

# PREMOLARE MORPHOLOGY

---



Dental Anatomi  
Prodi Kedokteran Gigi  
FKIK UMY

# MAXILLARY FIRST PREMOLARE

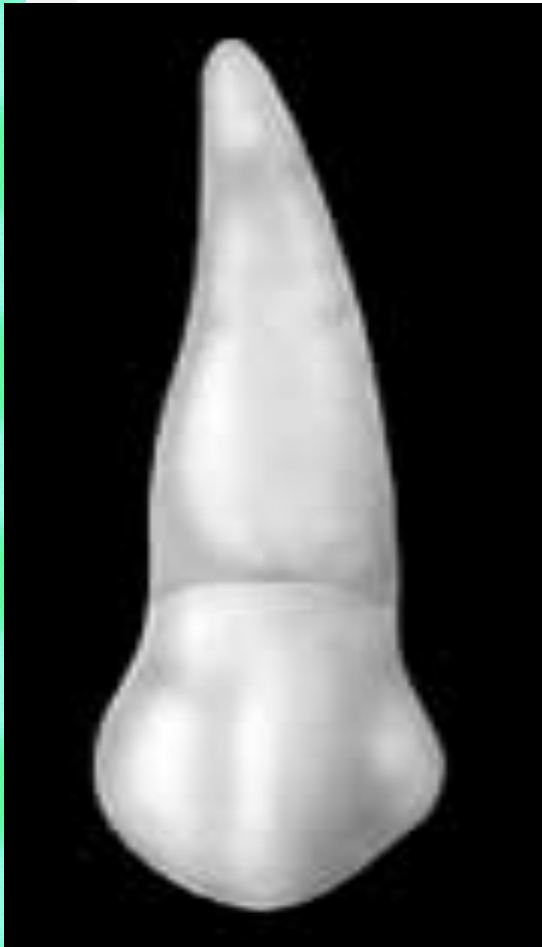---

---

- Evidence of calcification 1,5 years
- Enamel completed 5-6 years
- Eruption 10-11 years
- Root completed 12-13 years
  
- Crown peralihan dari gigi anterior ke molar
- Dari depan spt caninus
- Bucal perkembang dari 3 lobe, lingual dari 1 lobe

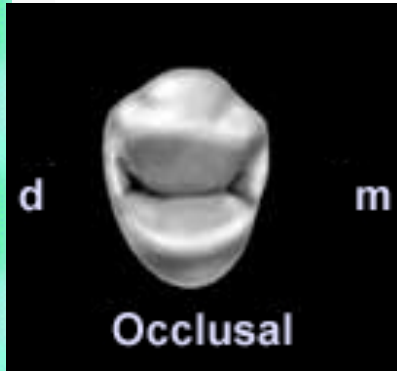


# Buccal aspect

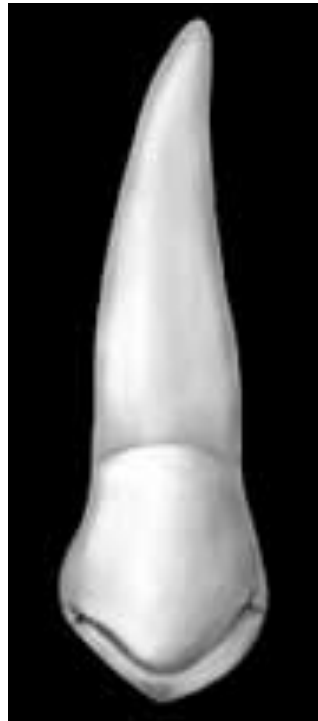

- Convex
- Incisal ridge berbentuk V
- Ada crista berjalan dari oklusal ke cervix disbt crista bucalis yg membagi menjadi :
  - Facies mesio bucal
  - Facies disto buccal

# Occlusal aspect

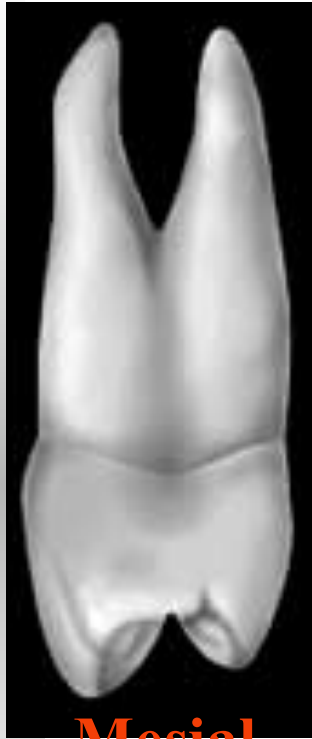

palatal



- Ada 2 cusp, bucal dan lingual
- Cusp buccal > besar, tinggi
- cusp palatal tajam
- Puncak cusp bucal di tengah (mir>dir)
- Puncak cusp palatal ke arah mesial
- Groove berbtk huruf V
- Facies oklusal hexagonal

# Proximal & Radix aspect

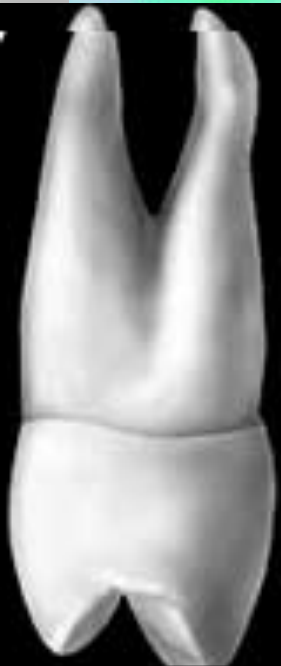

## Proximal aspect

- Sebelah mesial > concaaf dari distal

## Radik aspect

- 2, bucal & palatinal
- Bucal > panjang & besar
- Canal pulp 2
- Ada sulkus sepanjang sisi akar
- Tipe radix:
  - Jelas 2 radix
  - 2 radix bersatu, apex m'belah
  - 2 radix bersatu sampai apex



Distal

# MAXILLARY SECOND PREMOLARE

---

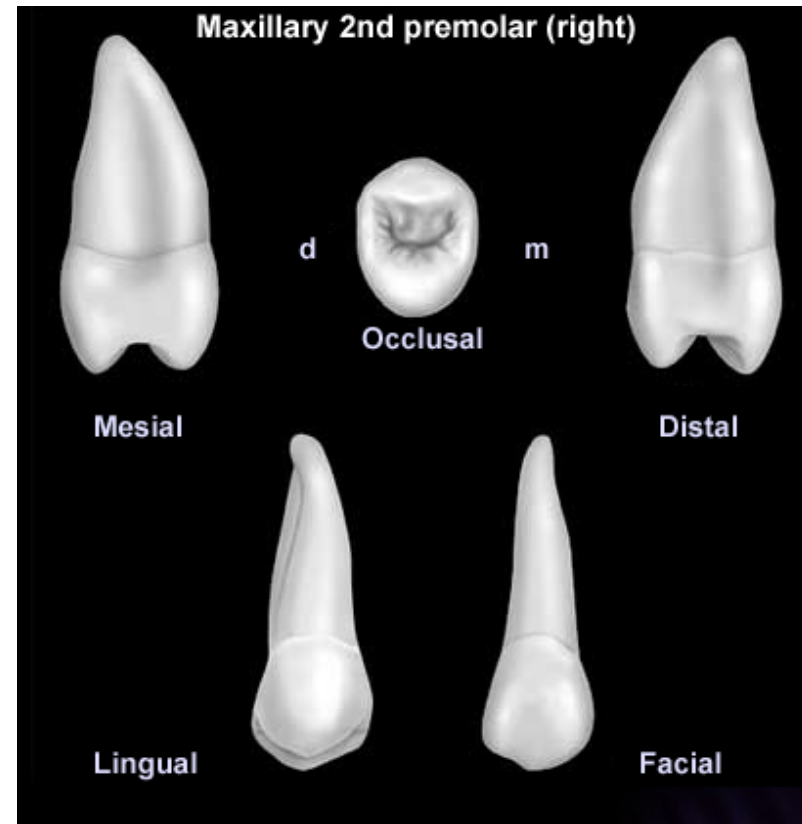


- Evidence of calcification 2 years
- Enamel completed 6-7 years
- Eruption 10-12 years
- Root completed 12-14 years



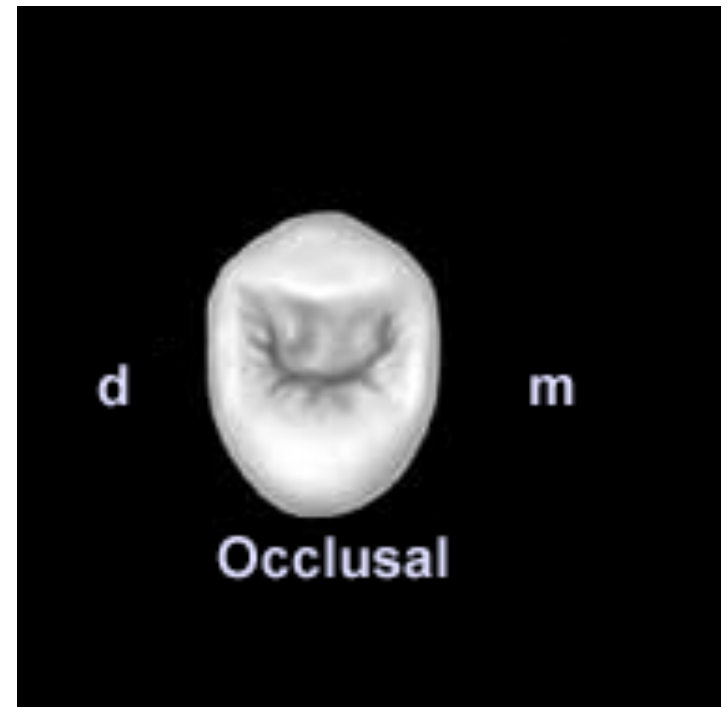
Hampir sama dengan P1 ats baik bentuk maupun fungsinya

- Besar tonjol bucal & palatinal hampir sama
- Bucal cusp ditengah, palatal > mesial
- Radix 1, pulp canal 1



# Oclusal aspect

- Facies oklusalis & bucalis hampir sam P1 atas
- Out line oklusalis lebih lancip dan bulat
- Groove tidak teratur





# MANDIBULLARY FIRST PREMOLARE

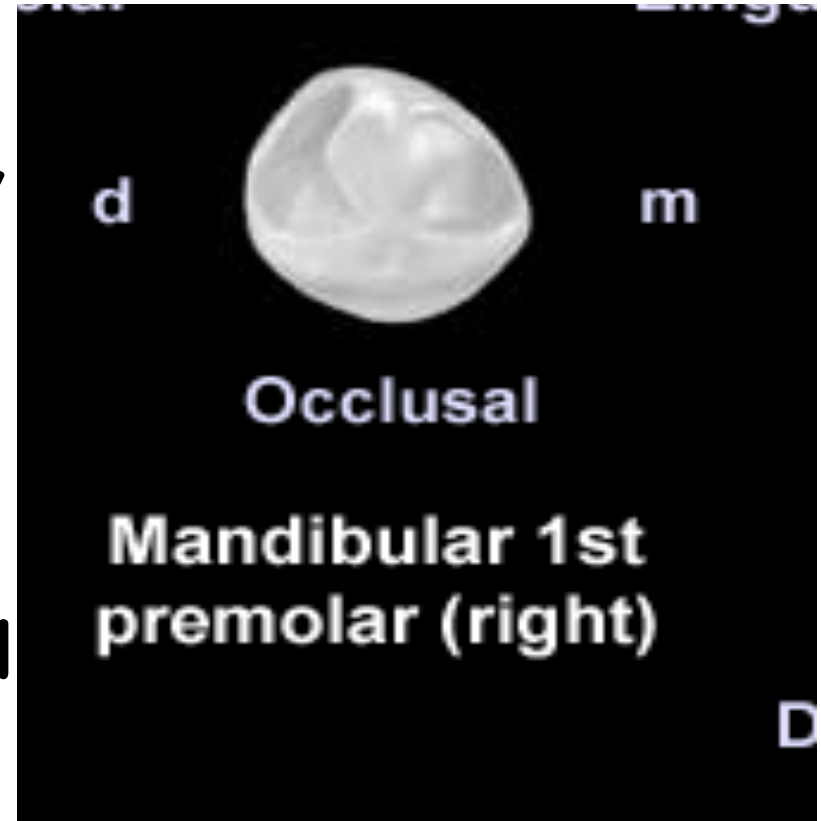


- Evidence of calcification 2 years
- Enamel completed 5-6 years
- Eruption 10-12 years
- Root completed 12-13 years
- Geraham terkecil di rahangbawah

# Occlusal aspect



- Hampir bulat
- 2 tonjol, 1 bucal, 1 lingual
- Tonjol bucal > tinggi dari lingual
- Mir<dir
- 2 fossa di oklusal distal > dari mesial



# Facial & lingual aspect

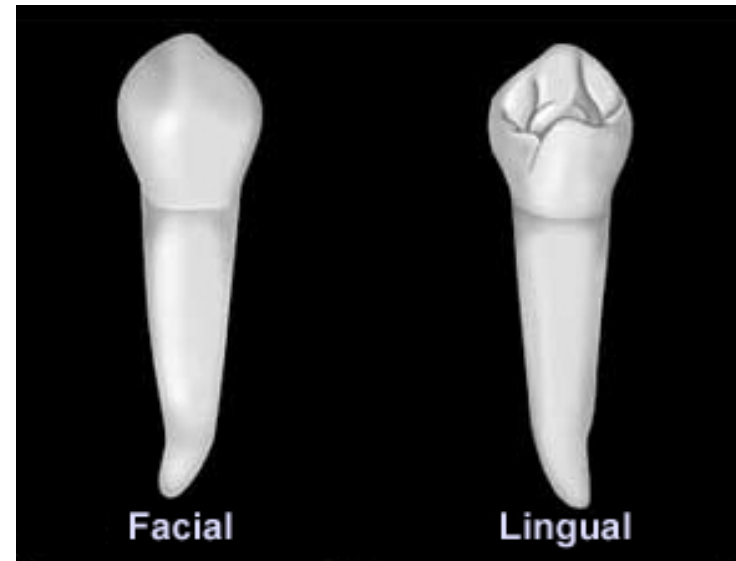


## Facial aspect

- Dari facial menyerupai caninus
- Convex (kronenflutcht)

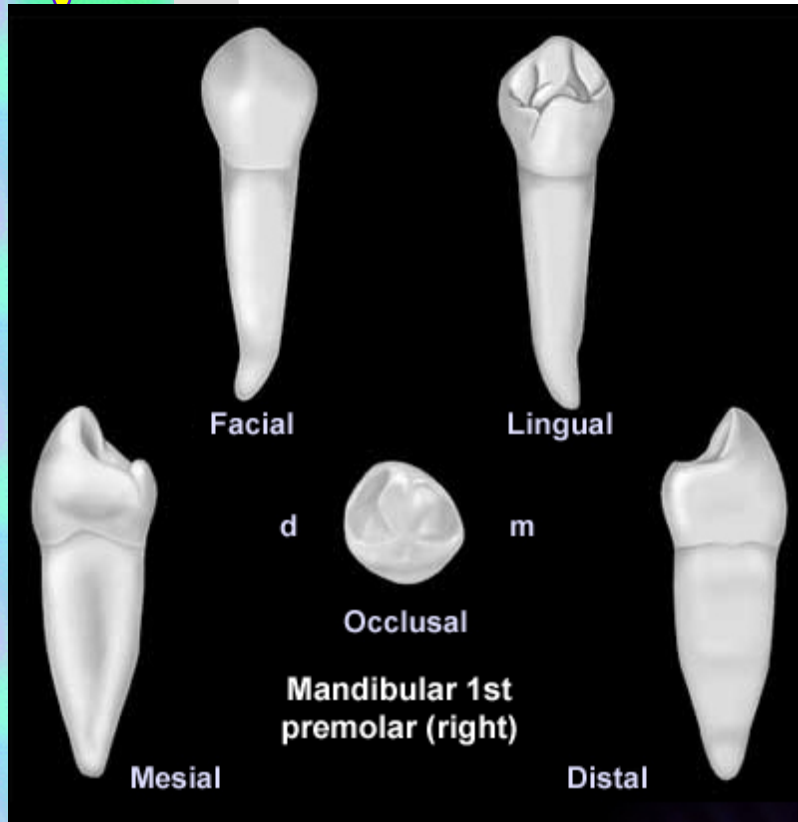
## Lingual aspect

- Permukaan hampir lurus





## Radix aspect




- Satu, pulp canal 1
- Akar meruncing ke bawah
- 1/3 apical akar menjadi lebih ramping
- Akar bengkok ke distal
- Sulcus bagian mesial lebih jelas

# MANDIBULLARY SECOND PREMOLARE

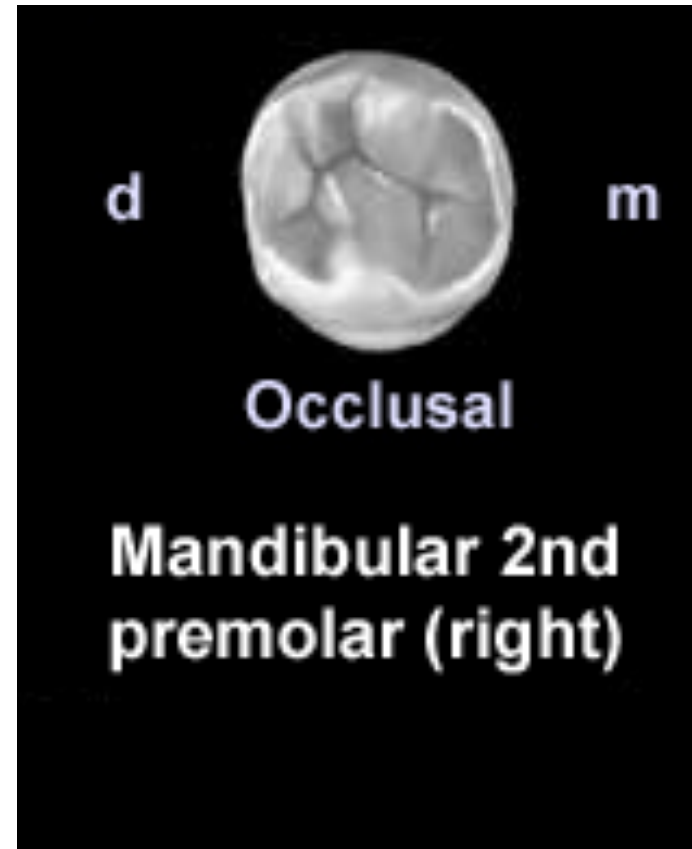


- Evidence of calcification 2,5 years
- Enamel completed 6-7 years
- Eruption 11-12 years
- Root completed 13-14 years

# Occlusal aspect



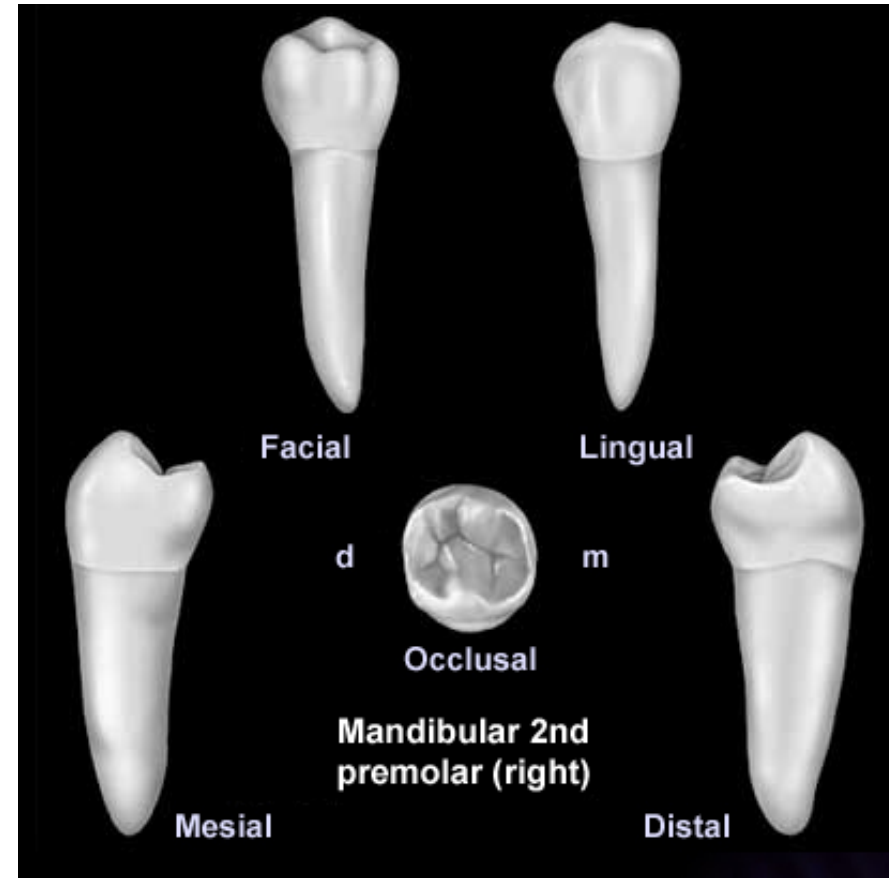
- Fac occlusalis hampir segi empat
- Bertonjol 2 dan 3
- Bertonjol 2 (1 bucal, 1 lingual)
- Bertonjol 3 (1 bucal, 2 lingual)
- Padatonjol 3, bucal cusp besar
- Fisura bertonjol 2, tipe U dan H
- Fissura 3 tonjol tipe Y



# Radix aspect



- Satu, pulp canal 1
- Kalo berbelok ke arah distal
- Tidak ada sulkus



# SELESAI

