



• www.umy.ac.id

INFEKSI VIRUS PADA KULIT

Siti Aminah Tri Susila Estri



Do'a belajar



**Asyhadu anlaa ilaaha illalloh
wa asyhadu anna Muhammadan
rasuululloh**

**Rodliitu billaahi robbaa
wa bil-istaami diinaa
wa bi Muhammadin nabiiyaw wa
rosuulaa**

**Robbi zidnii 'ilmaa
warzuqnii fahmaa
Aamiin....**

Siti Aminah Tri Susila Estri

- Address: Sariharjo, Ngaglik, Sleman
- Phone: 085228074851
- E-mail: aminahtsel@umy.ac.id; aminah.satse@gmail.com

- facebook.com
- twitter.com
- Instagram.com

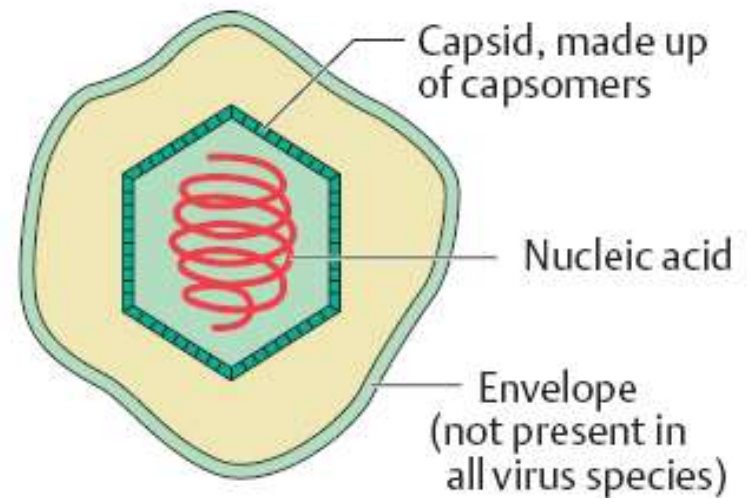
Tujuan Belajar

1. Mengetahui jenis infeksi virus pada kulit
2. Mengetahui faktor penyebab dan faktor risiko infeksi virus pada kulit
3. Memahami cara penegakan diagnosis penyakit infeksi virus pada kulit
4. Memahami cara dan interpretasi hasil pemeriksaan penunjang
5. Memahami cara penatalaksanaan penyakit infeksi virus pada kulit.

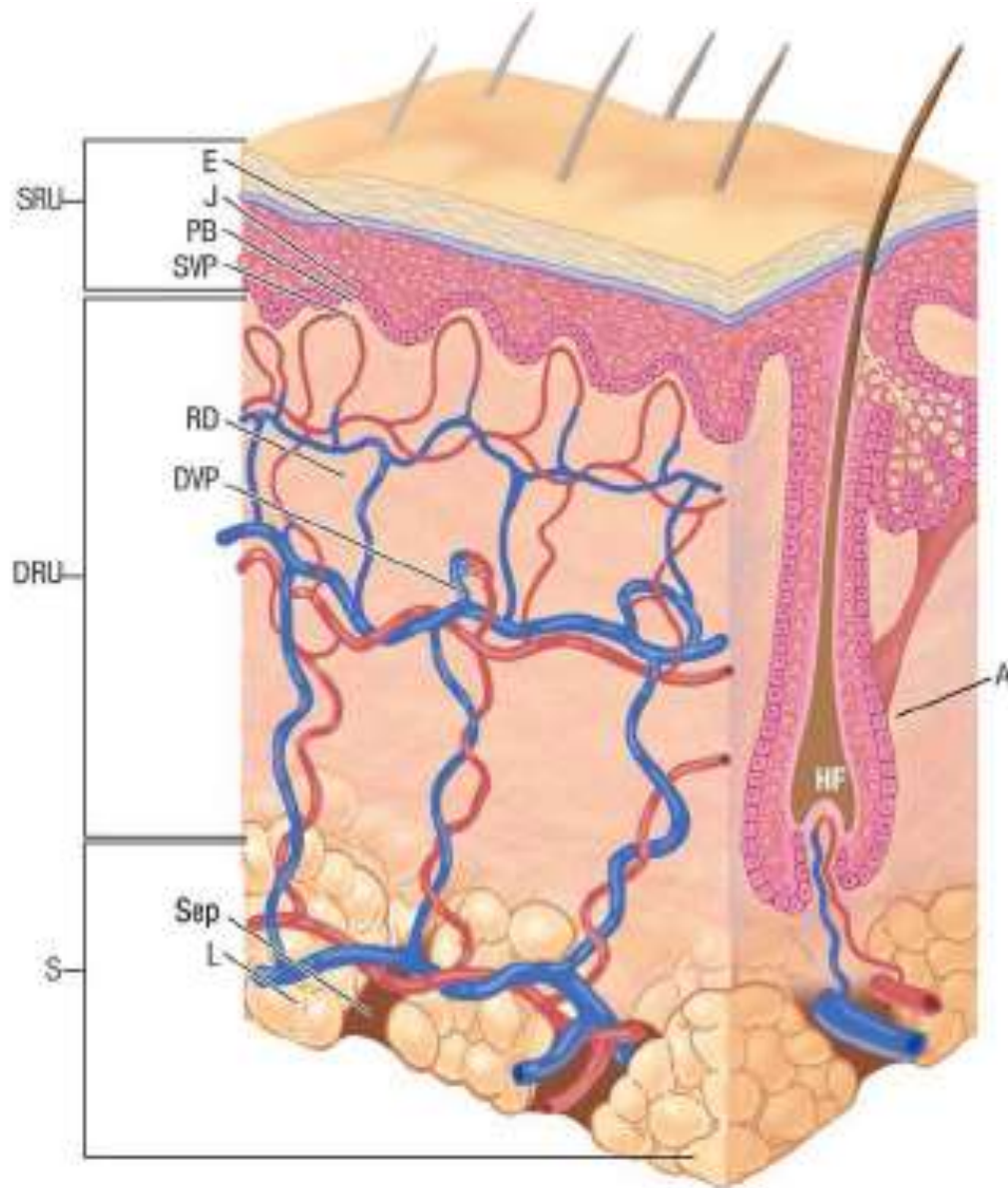
Struktur Virus

1. Envelope (virus tertentu)
2. Capsid (protective protein coat)
3. Genome (DNA, RNA)

- Virus Particle Structure



Struktur Kulit



Jenis Virus dan penyakitnya

- Herpes virus (DNA, infeksi laten, rekuren) → Herpes simpleks, varicella, Herpes zoster
- Papovavirus (DNA, tanpa envelope) → veruka, kondiloma
- Poxvirus (DNA) → moluskum kontagiosum
- Paramyxovirus (RNA) → eksantema virus
- Picornavirus (=enterovirus, RNA) → eksantema virus
- Retroviruses (RNA, HIV) → eksantema virus

SKDI 2012

<i>Infeksi Virus</i>		
1	Veruka vulgaris	4A
2	Kondiloma akuminatum	3A
3	Moluskum kontagiosum	4A
4	Herpes zoster tanpa komplikasi	4A
5	Morbili tanpa komplikasi	4A
6	Varisela tanpa komplikasi	4A
7	Herpes simpleks tanpa komplikasi	4A

SNPPDI 2021

	Infeksi Virus	
1	Veruka vulgaris	3A
2	Kondiloma akuminata	3A
3	Moluskum kontagiosum	3A
4	Varisela	4
5	Herpes zoster (non oftalmikus dan non diseminata)	4
6	Post herpetik neuralgia	3A
7	Morbili/ campak	4
8	Rubela	3A
9	Herpes simpleks tanpa komplikasi	4
10	Hand, mouth and foot disease	3A

Herpesvirus :

1. Virus Herpes Simplex

Infeksi primer (pertama kali)

- Penularan melalui kontak dengan lesi penderita (mukosa, sekret) dengan kulit yg tidak intak atau mukosa.
- Virus menginfeksi sel basal → sel lisis (degenerasi balon) → vesikel, inflamasi
- Saraf sensoris perifer → ganglion sensoris (trigeminus, sacral) atau saraf otonom (N.X)

S

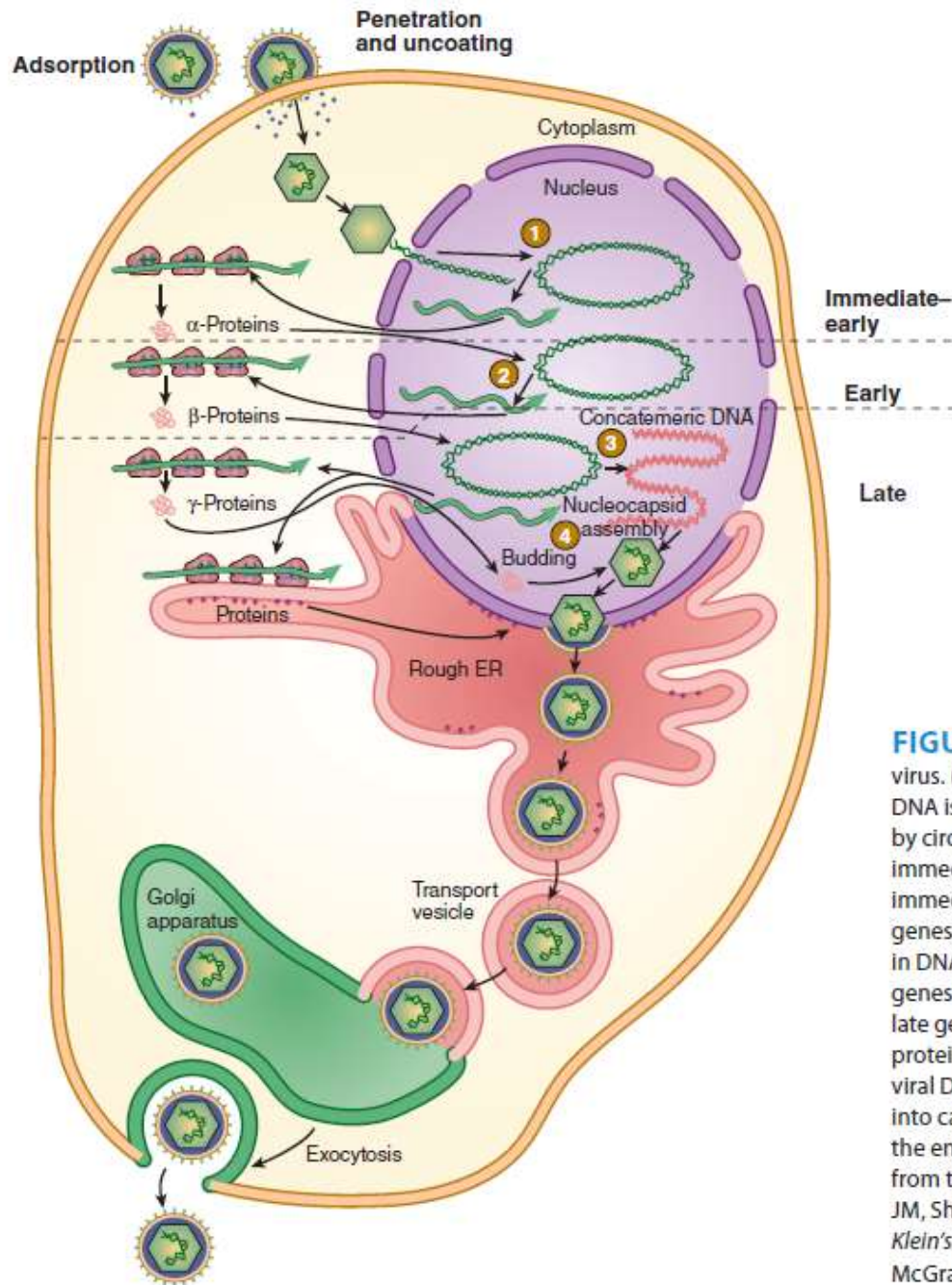
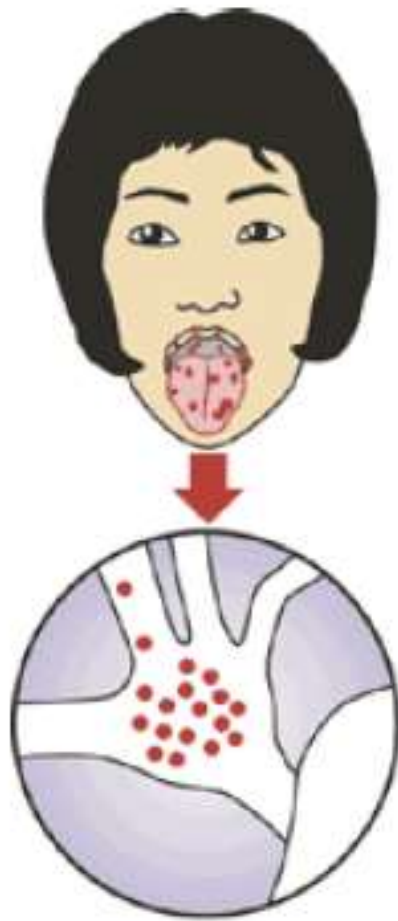
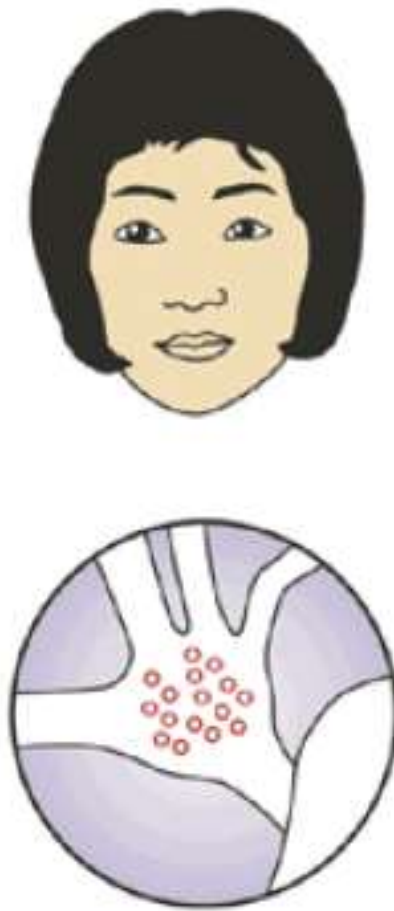


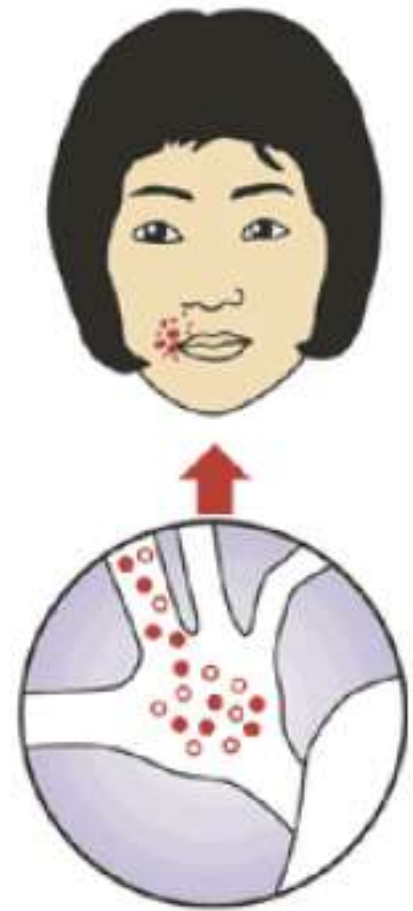
FIGURE 33-2 Replication cycle of herpes simplex virus. (1) Virus fuses with plasma membrane, and viral DNA is released from capsid at nuclear pore followed by circularization of genome and transcription of immediate-early genes. (2) α -Proteins, products of immediate-early genes, stimulate transcription of early genes. (3) β -Proteins, products of early genes, function in DNA replication, yielding concatemeric DNA. Late genes are transcribed. (4) γ -Proteins, products of late genes and consisting primarily of viral structural proteins, participate in virion assembly. Unit-length viral DNA is cleaved from concatemers and packaged into capsids. Enveloped viral particles accumulate in the endoplasmic reticulum (ER) and are transported from the cell. (Reproduced with permission from Willey JM, Sherwood LM, Woolverton CJ: *Prescott, Harley, and Klein's Microbiology*, 7th ed. McGraw-Hill, 2008. © The McGraw-Hill Companies, Inc.)



A Primary infection



B Latent phase



C Recurrence

Copyright ©2006 by The McGraw-Hill Companies, Inc.
All rights reserved.

Herpesvirus :

1. Virus Herpes Simplex

Infeksi laten (Infeksi rekuren),

- Pada 1/3 penderita infeksi herpes labialis,
- Akibat sinar UV, ketidakseimbangan hormon, demam, gangguan imunitas.
- Aktivasi dan sintesis virus pada ganglion saraf sensoris atau otonom
- Virus migrasi ke perifer melalui serabut saraf sensoris, menuju kulit atau mukosa
→ menginfeksi sel parabasal → sel lisis
(degenerasi balon) → vesikel, inflamasi

Herpesvirus :

1. Virus Herpes Simplex

Epidemiologi

- Herpes labialis : serologi HSV-1 80-90%, HSV-2 10-20%
- Herpes urogenitalis : serologi HSV-2 70-90%, HSV-1 10-30%
- Herpetic whitlow : < 20 th HSV-1, > 20 th HSV-2, neonatal HSV-2 70%

Herpesvirus :

1. Virus Herpes Simplex

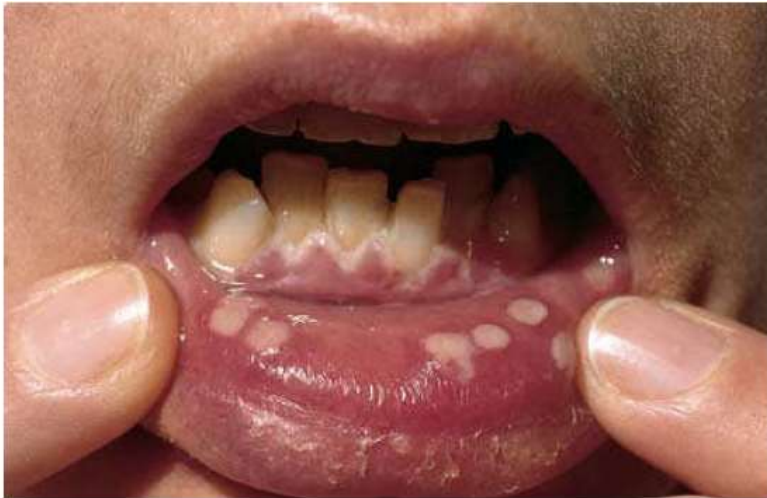Manifestasi klinis

- Herpes labialis & urogenitalis

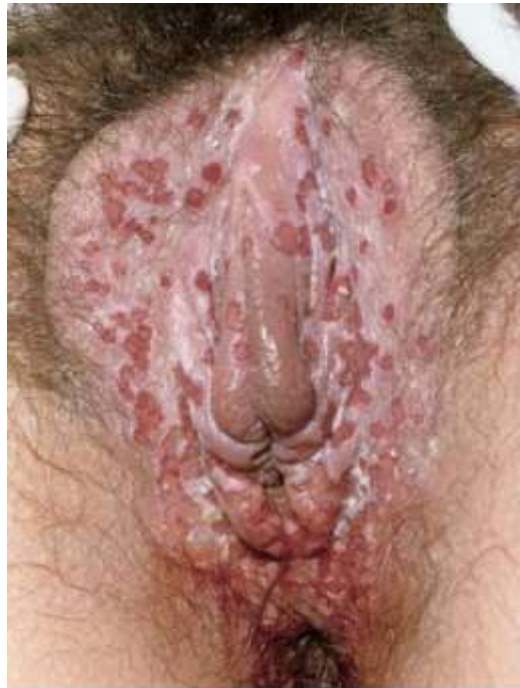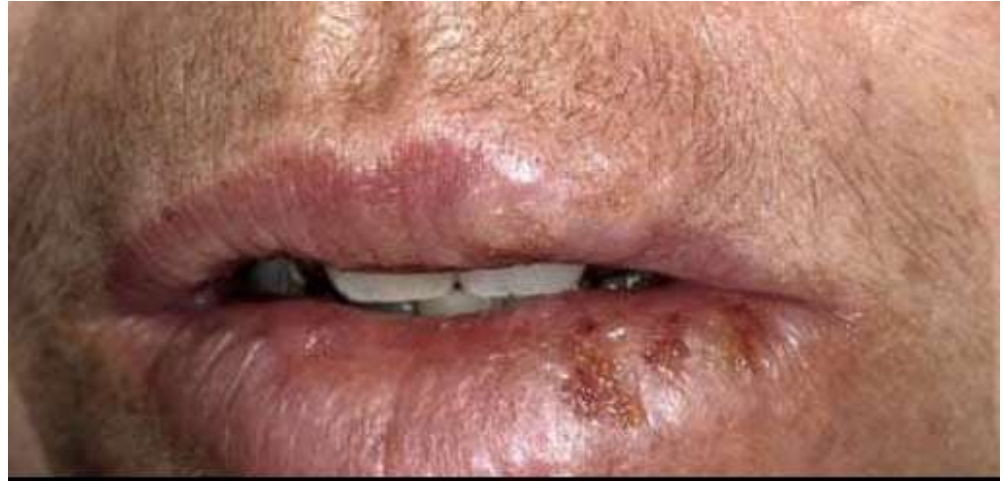- Infeksi primer : gejala sistemik, lesi : vesikel, erosi, multipel, berkelompok, dengan rasa nyeri, panas, menyembuh dalam waktu 2-4 minggu.

Lokasi : orofaring, labium, perioral, tempat lain (jari distal)

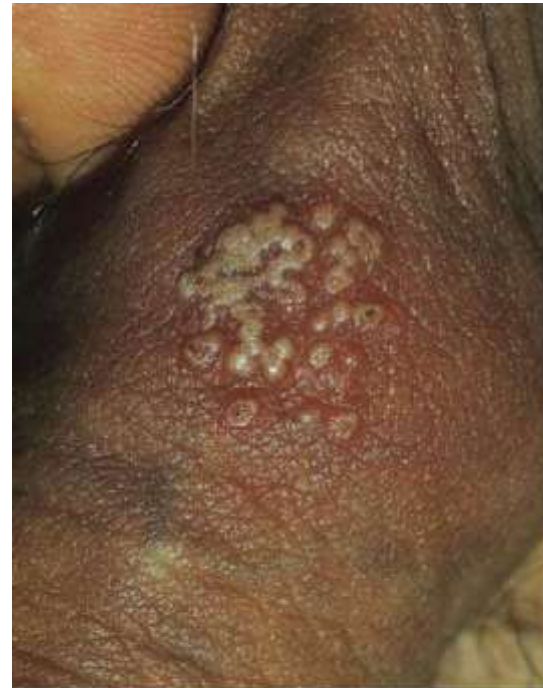- Infeksi rekuren : gejala sistemik (-), lesi lebih ringan, rasa nyeri +/-, menyembuh dalam waktu 1-2 minggu



Copyright ©2006 by The McGraw-Hill Companies, Inc.
All rights reserved.



Copyright ©2006 by The McGraw-Hill Companies, Inc.
All rights reserved.



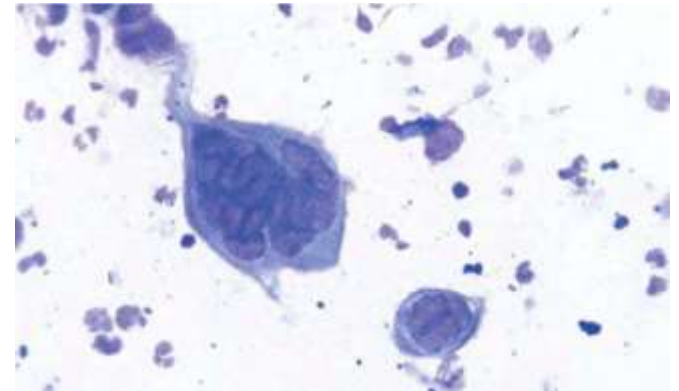
Copyright ©2006 by The McGraw-Hill Companies, Inc.
All rights reserved.

Herpes virus :

1. Virus Herpes Simplex

- Penegakan Dx

- Anamnesis
- Pemeriksaan fisik (sarung tangan)
- Penunjang : tes Tzank, serologi (IgG dan IgM antiHSV-1 dan -2), deteksi Ag VVZ (direct fluorescent ab test=DFA), dermatopatologi (biopsi), kultur virus, PCR



Herpesvirus :

1. Virus Herpes Simplex

Penatalaksanaan

- Terapi

Prevention

Skin-to-skin contact should be avoided during outbreak of cutaneous HSV infection.

Topical Antiviral Therapy

Approved for herpes labialis; minimal efficacy.

Acyclovir 5% ointment

Apply q3h, 6 times daily for 7 days. Approved for initial genital herpes and limited mucocutaneous HSV infections in immunocompromised individuals.

Penciclovir 1% Cream

Apply q2h while awake for recurrent orolabial infection in immunocompetent individuals.

Oral Antiviral Therapy

Currently, anti-HSV agents are approved for use in genital herpes. Presumably similar dosing regimens are effective for nongenital infections. Drugs for oral HSV therapy include acyclovir, valacyclovir, and penciclovir. Valacyclovir, the prodrug of acyclovir, has a better bioavailability and is nearly 85% absorbed after oral administration. Penciclovir is equally effective for cutaneous HSV infections.

First episode

Antiviral agents more effective in treating primary infections than recurrences

Acyclovir

400 mg tid or 200 mg 5 times daily for 7–10 days

Valacyclovir

1 g bid for 7–10 days

Penciclovir

250 mg tid for 5–10 days

Recurrences

Most episodes of recurrent herpes do not benefit from pulse therapy with oral acyclovir. In severe recurrent disease, patients who start therapy at the beginning of the prodrome or within 2 days after onset of lesions may benefit from therapy by shortening and reducing severity of eruption; however, recurrences cannot be prevented.

Acyclovir

400 mg PO tid for 5 days *or*

800 mg PO bid for 5 days

Valacyclovir

500 mg bid for 5 days *or* 2 g bid for day 1, then 1 g bid on day 2

Penciclovir

125 mg bid for 5 days

Chronic suppression

Decreases frequency of symptomatic recurrences and asymptomatic HSV shedding. After 1 year of continuous daily suppressive therapy, acyclovir should be discontinued to determine the recurrence rate.

Acyclovir

400 mg bid

Valacyclovir

500–1000 mg qd

Penciclovir

250 mg bid

Herpesvirus :

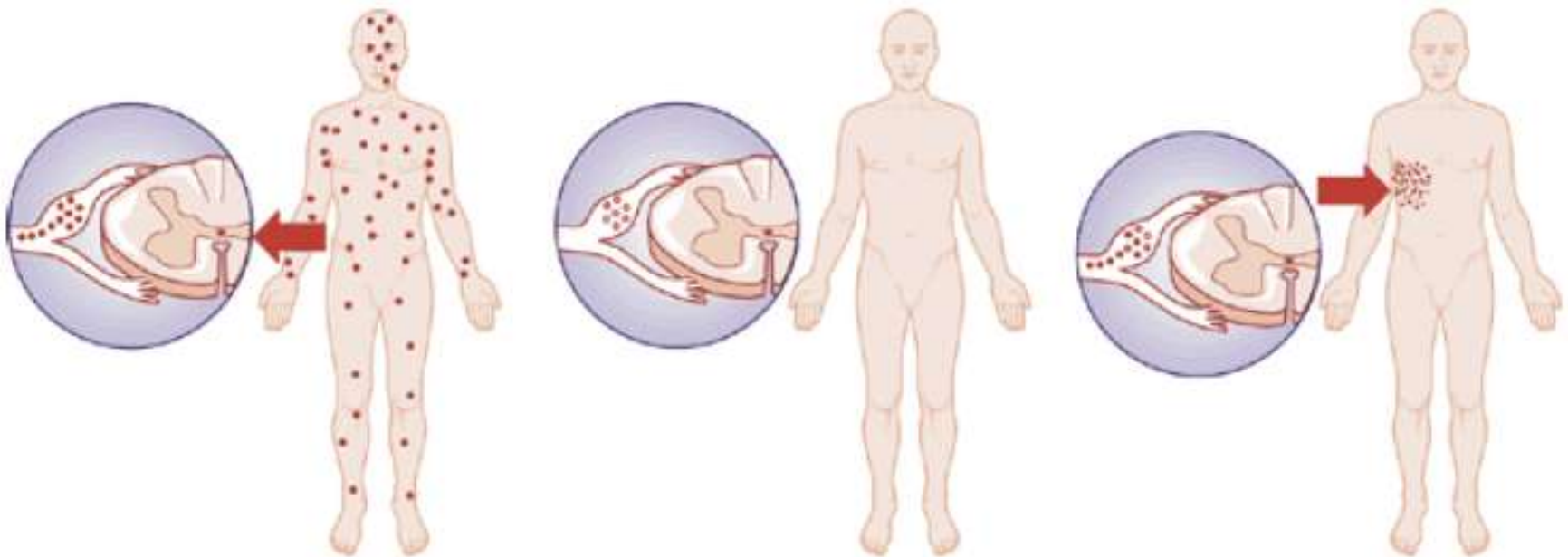
2. Virus Varicella Zoster (VVZ)

Infeksi primer, disebut juga **Varicella**

- Merupakan Infeksi VVZ pertama kali
- Penularan melalui kontak langsung dengan lesi penderita atau *airborne droplet*, pada waktu masa inkubasi sampai lesi vesikel terakhir muncul.
- Virus masuk saluran pernafasan → replikasi lokal → viremia primer → replikasi pada RES → viremia sekunder, penyebaran ke kulit dan mukosa (menginfeksi sel parabasal → **sel lisis (degenerasi balon) → vesikel, inflamasi**)
- Viremia → gejala sistemik
- Melalui saraf sensoris perifer → ganglion saraf sensoris → infeksi laten

Herpesvirus :

2. Virus Varicella Zoster



A Chickenpox

B Latent phase

C Herpes zoster

Copyright ©2006 by The McGraw-Hill Companies, Inc.
All rights reserved.

Herpesvirus :

2. Virus Varicella Zoster

Infeksi rekuren, disebut juga **Herpes Zoster**

- Akibat replikasi VVZ pada ganglion saraf sensoris
- Akibat imunitas tubuh melemah
- Virus menuju kulit melalui saraf sensoris
→ dermatomal pain, menginfeksi sel parabasal → sel lisis (degenerasi balon) → vesikel, inflamasi)
- Neuralgia paska herpetik : fibrosis/distrofi saraf perifer → nyeri

Herpesvirus :

2. Virus Varicella Zoster

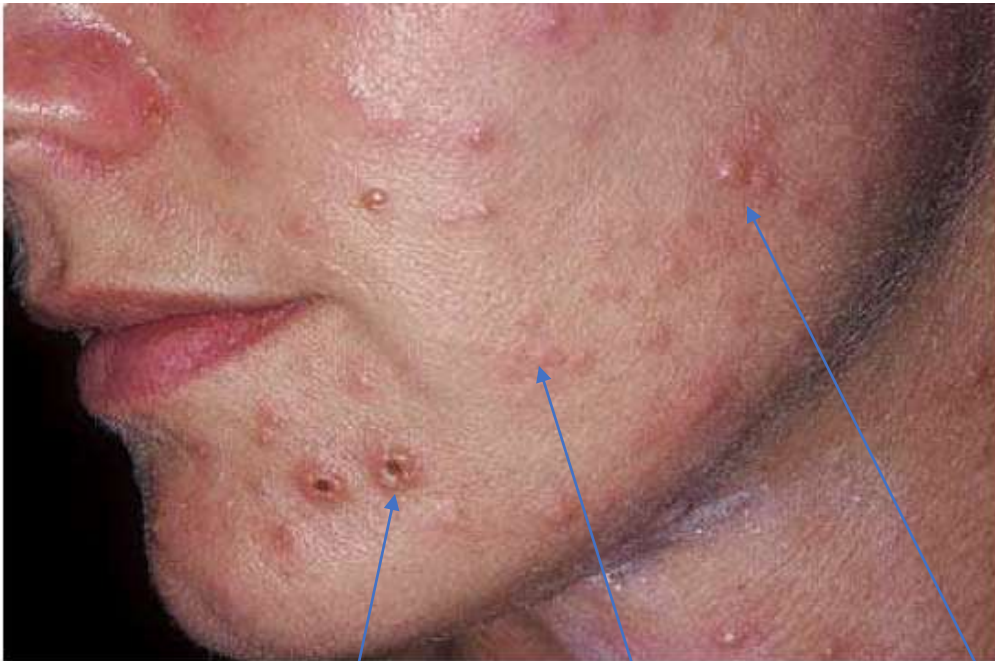Manifestasi Klinis :

Varicella

- Inkubasi 10-23 hari (14 hari)
- Prodromal : anak-anak → tidak ada, ringan; dewasa : nyeri seluruh tubuh, lemah, demam; eksantem terlihat pada hari 2-3, disertai rasa gatal
- Lesi : papul → vesikel umbilikated → pustul → krusta → lepas → hiperpigmentasi paska inflamasi
- Distribusi : wajah, kepala → badan dan ekstremitas

Herpesvirus :

2. Virus Varicella Zoster



Copyright ©2006 by The McGraw-Hill Companies, Inc.
All rights reserved.

Gb. Varicella, dengan diskripsi lesi:

Pada wajah & leher: papul eritem, vesikel, sebagian dengan krusta (umbilikated), multiple, tersebar.

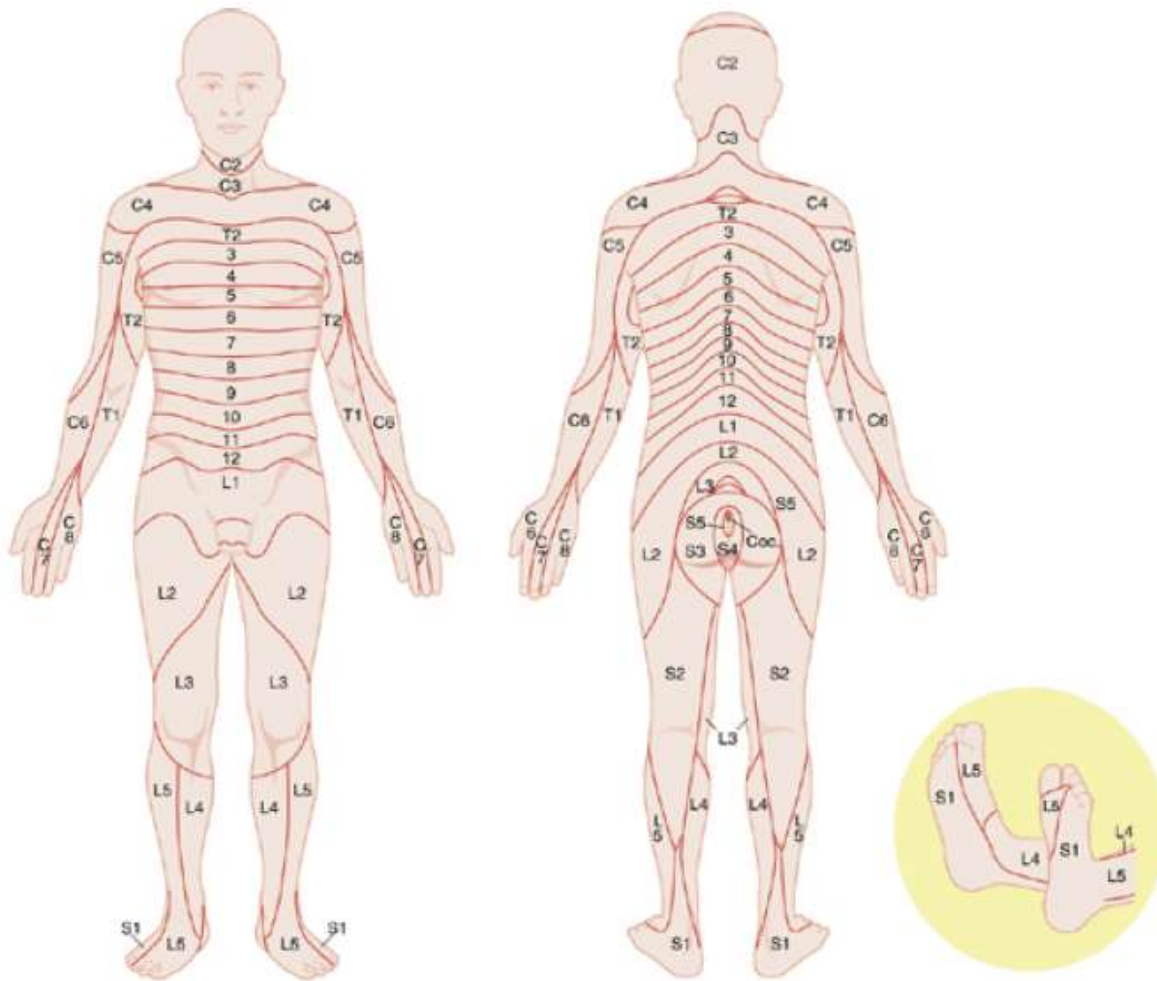
Herpesvirus :

2. Virus Varicella Zoster

Manifestasi Klinis :

Herpes zoster

- Prodromal : nyeri, alodinia, neuritis 2-3 minggu, gejala sistemik
- Vesikulasi akut: 3-5 hari, gatal ringan, lesi: papul → vesikel, multipel berkelompok/zosteriform, **sesuai dermatom saraf tertentu**, gejala sistemik +/-
- Pembentukan krusta beberapa hari s/d 2-3 minggu, kadang disertai rasa gatal
- Komplikasi tersering **neuralgia paska herpetik**, yg terjadi dalam beberapa bulan sampai tahun, disertai rasa nyeri, pegal, panas, dll



A

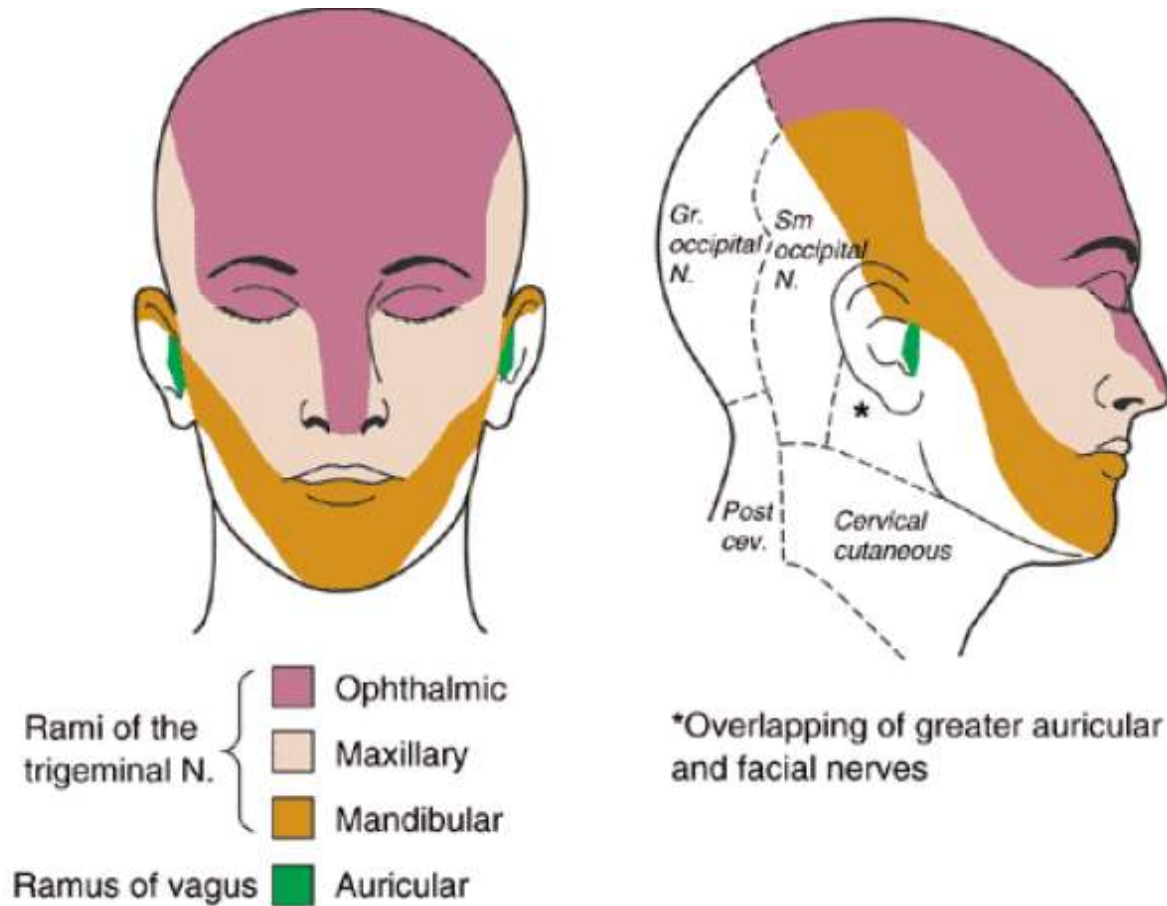
B

Copyright ©2006 by The McGraw-Hill Companies, Inc.
 All rights reserved.

Skema Gambaran Dermatome Kulit

Herpesvirus :

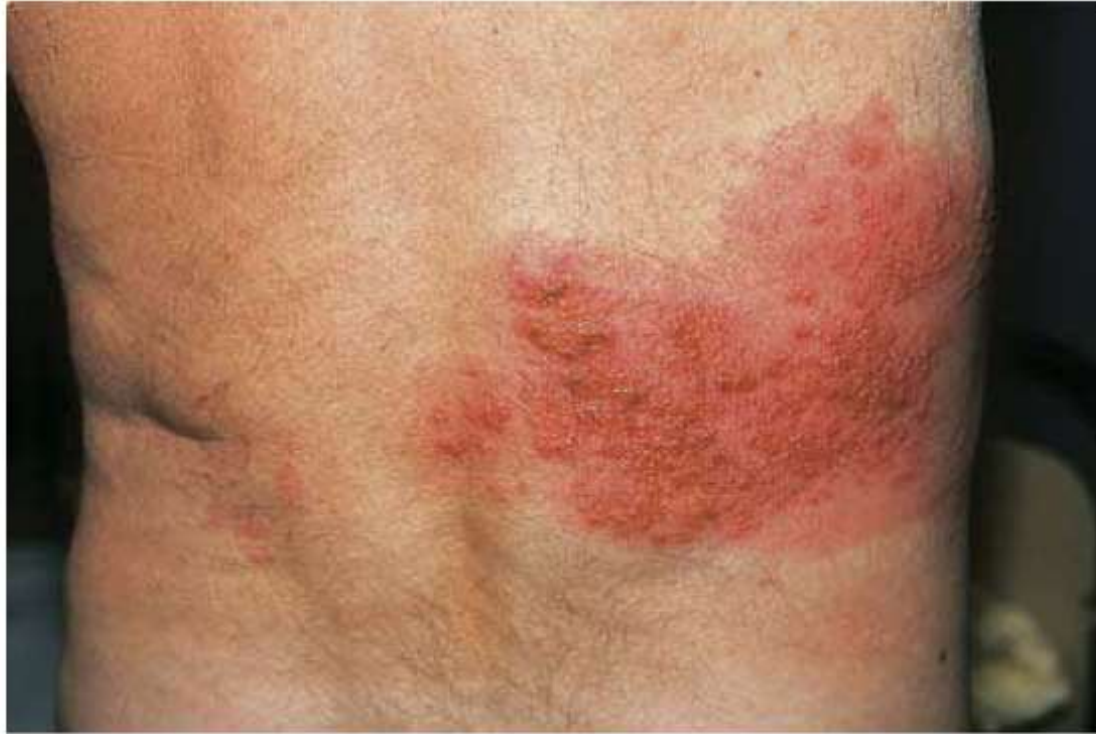2. Virus Varicella Zoster



C

Copyright ©2006 by The McGraw-Hill Companies, Inc.
All rights reserved.

Dermatomes The cutaneous fields of peripheral nerves.

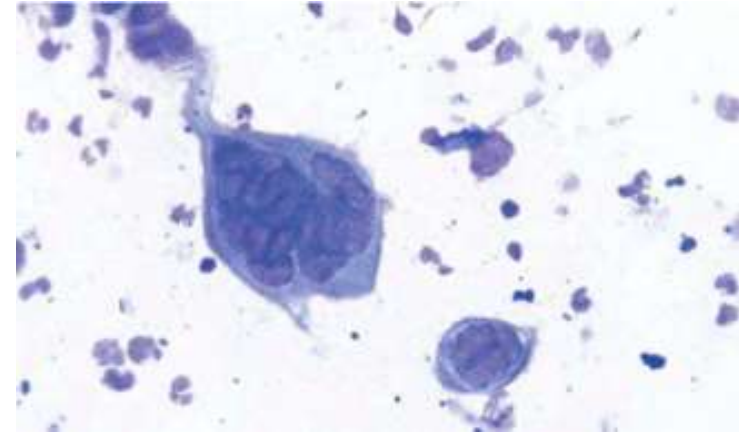


Copyright ©2006 by The McGraw-Hill Companies, Inc.
All rights reserved.

Gb Lesi Herpes zoster: papul eritem dan vesikel dengan dasar eritem, multipel, berkelompok.

Herpesvirus :

2. Virus Varicella Zoster



Penatalaksanaan

- Penegakan Dx
 - Anamnesis
 - Pemeriksaan fisik (sarung tangan)
 - Penunjang :
 - tes Tzank,
 - deteksi Ag VVZ (direct fluorescent antibody test=DFA), dermatopatologi (biopsi), kultur virus

Terapi

1. Sistemik

Antivirus diberikan tanpa melihat waktu timbulnya lesi pada³: (D,5*)

- Usia >50 tahun
- Dengan risiko terjadinya NPH
- HZO/sindrom Ramsay Hunt/HZ servikal/HZ sakral
- Immunokompromais, diseminata/generalisata, dengan komplikasi
- Anak-anak, usia <50 tahun dan ibu hamil diberikan terapi anti-virus bila disertai NPH, sindrom Ramsay Hunt (HZO), immunokompromais, diseminata/generalisata, dengan komplikasi

Pilihan antivirus

- Asiklovir oral 5x800 mg/hari selama 7-10 hari.^{3,5} (A,1)
- Dosis asiklovir anak <12 tahun 30 mg/kgBB/hari selama 7 hari, anak >12 tahun 60 mg/kgBB/hari selama 7 hari.³
- Valasiklovir 3x1000 mg/hari selama 7 hari⁶⁻⁸ (A,1)
- Famsiklovir 3x250 mg/hari selama 7 hari^{6,9} (A,1)

Simptomatik

- Nyeri ringan: parasetamol 3x500 mg/hari atau NSAID.^{3,14} (D,5*)
- Nyeri sedang-berat: kombinasi dengan tramadol atau opioid ringan.^{3,14} (D,5*)
- Pada pasien dengan kemungkinan terjadinya neuralgia pasca herpes zoster selain diberi asiklovir pada fase akut, dapat diberikan:
 - Antidepresan trisiklik (amitriptilin dosis awal 10 mg/hari ditingkatkan 20 mg setiap 7 hari hingga 150 mg. Pemberian hingga 3 bulan, diberikan setiap malam sebelum tidur^{3,15} (A,1)
 - Gabapentin 300 mg/hari 4-6 minggu^{3,16} (A,1)
 - Pregabalin 2x75 mg/hari 2-4 minggu.^{3,16} (A,1)

Herpes zoster oftalmikus

- Asiklovir/valasiklovir diberikan hingga 10 hari pada semua pasien.^{3,17} (A,1)
- Rujuk ke dokter spesialis mata.

Herpes zoster otikus dengan paresis nervus fasialis

- Asiklovir/valasiklovir oral 7-14 hari dan kortikosteroid 40-60 mg/hari selama 1 minggu pada semua pasien.¹⁸ (A,1)
- Rujuk ke dokter spesialis THT.

2. Topikal

- Stadium vesikular: bedak salisil 2% untuk mencegah vesikel pecah atau bedak kocok kalamín untuk mengurangi nyeri dan gatal.²⁰ (C,5)
- Bila vesikel pecah dan basah dapat diberikan kompres terbuka dengan larutan antiseptik dan krim antiseptik/antibiotik.^{3,20} (C,5)
- Jika timbul luka dengan tanda infeksi sekunder dapat diberikan krim/salep antibiotik.^{3,20}

Neuralgia pasca herpes

1. Terapi farmakologik:

- Terapi farmakologi lini pertama: masuk dalam kategori efektivitas sedang-tinggi, berbasis bukti yang kuat dan dengan efek samping rendah.
- Lini pertama:
 - Antidepresan trisiklik 10 mg setiap malam (ditingkatkan 20 mg setiap 7 hari menjadi 50 mg, kemudian menjadi 100 mg dan 150 mg tiap malam)^{3,16,21} (A,1)
 - Gabapentin 3x100 mg (100-300 mg ditingkatkan setiap 5 hari hingga dosis 1800-3600 mg/hari)^{3,16,21} (A,1)
 - Pregabalin 2x75 mg (ditingkatkan hingga 2x150 mg/hari dalam 1 minggu)^{3,16,22} (A,1)
 - Lidokain topikal (lidokain gel 5%, lidokain transdermal 5%)^{3,23} (A,1)
- Lini kedua:
 - Tramadol 1x50 mg (tingkatkan 50 mg setiap 3-4 hari hingga dosis 100-400 mg/hari dalam dosis terbagi)^{3,24} (A,1)

2. Terapi nonfarmakologik: masuk dalam kategori *reports of benefit limited*

- Neuroaugmentif: *counter irritation*³ (C,5), *transcutaneous electrical nerve stimulation (TENS)*²⁵⁻²⁶ (A,1), *deep brain stimulation*²⁷⁻²⁸ (C,4), akupunktur^{29,30} (C,4), *low intensity laser therapy*³ (C,5)
- Neurosurgical³
- Psikososial³

Edukasi

1. Memulai pengobatan sesegera mungkin
2. Istirahat hingga stadium krustasi
3. Tidak menggaruk lesi
4. Tidak ada pantangan makanan
5. Tetap mandi
6. Mengurangi kecemasan dan ketidakpahaman pasien

Prognosis

Lesi kulit biasanya menyembuh dalam 2-4 minggu tetapi penyembuhan sempurna membutuhkan waktu >4 minggu. Pasien usia lanjut dan imunokompromais membutuhkan waktu yang lebih lama untuk resolusi. Dalam studi kohort retrospektif, pasien herpes zoster yang dirawat di rumah sakit memiliki mortalitas 3% dengan berbagai penyebab.³³ Tingkat rekurensi herpes zoster dalam 8 tahun sebesar 6,2%.³⁴

Prognosis tergantung usia.

1. Usia <50 tahun:
 - Ad vitam bonam
 - Ad functionam bonam
 - Ad sanationam bonam
2. Usia >50 tahun dan imunokompromais:
 - Ad vitam bonam
 - Ad functionam dubia ad bonam
 - Ad sanationam dubia ad bonam

Herpesvirus :

2. Virus Varicella Zoster

Terapi

Prevention

Immunization

Immunization with VZV vaccine may boost humoral and cell-mediated immunity and decrease the incidence of zoster in populations with declining VZV-specific immunity.

Goals of management

Relieve constitutional symptoms; minimize pain; reduce viral shedding; prevent secondary bacterial infection; speed crusting of lesions and healing; ease physical, psychological, emotional discomfort; prevent viral dissemination or other complications; prevent or minimize PHN.

Herpesvirus :

2. Virus Varicella Zoster

Antiviral therapy

In individuals at high risk for reactivation of VZV infection, oral acyclovir can reduce the incidence of HZ. In prodromal stage: begin antiviral agent if diagnosis is considered likely; analgesics. With active vesiculation: antiviral therapy begun \leq 72 h accelerates healing of skin lesions, decreases the duration of acute pain, and may decrease the frequency of PHN when given in adequate dosage.

Acyclovir

800 mg PO qid for 7–10 days. The 50% viral inhibitory concentration of acyclovir is three to six times higher for VZV than for HSV in vitro, and drug dose must be increased appropriately. The bioavailability of acyclovir is only 15 to 30% of the orally administered dose. For ophthalmic zoster and HZ in the immunocompromised host, acyclovir should be given intravenously. Acyclovir hastens healing and lessens *acute* pain if given within 48 h of the onset of the rash.

Valacyclovir

1000 mg PO tid for 7 days, 70 to 80% bioavailable.

Penciclovir

500 mg PO tid for 7 days, 77% bioavailable. Reduce dose in individuals with diminished renal function.

Acyclovir-resistant VZV

Foscarnet

Immunosuppressed *patients*

IV acyclovir and recombinant interferon α -2a to prevent dissemination of HZ is indicated.

Herpesvirus :

2. Virus Varicella Zoster

Supportive therapy for acute HZ

Constitutional symptoms	Bed rest, NSAIDs.
Sedation	Pain often interferes with sleep. Sleep deprivation and pain commonly result in depression. Doxepin, 10 to 100 mg hs, is an effective agent.
Oral glucocorticoids	Prednisone given early in the course of HZ relieves constitutional symptoms but has not been proven to reduce PHN.
Dressings	Application of moist dressings (water, saline, Burow's solution) to the involved dermatome is soothing and alleviates pain.
Pain management	Early control of pain with narcotic analgesics is indicated; failure to manage pain can result in failure to sleep, fatigue, and depression: Best to begin with more potent analgesics and then reduce potency as pain lessens.

Herpesvirus :

2. Virus Varicella Zoster

Chronic stages

(PHN)

Pain management

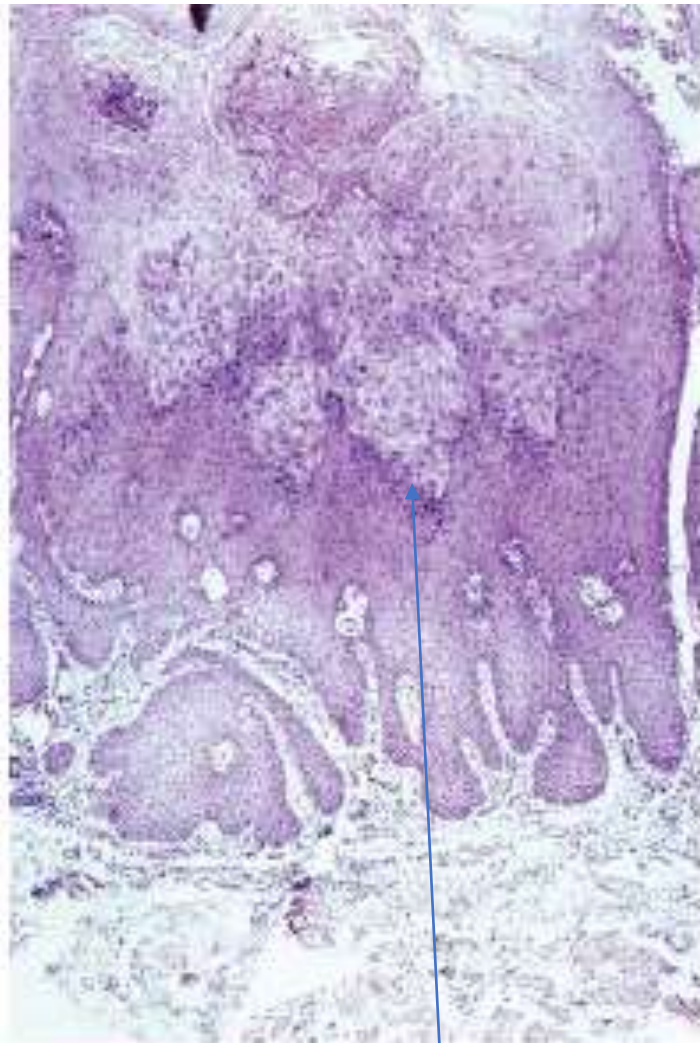
Pain is that of reflex sympathetic dystrophy.

Severe prodromal pain or severe pain on the first day of rash is predictive of severe PHN. Gabapentin: 300 mg tid. Tricyclic antidepressants such as doxepin, 10 to 100 mg PO hs. Capsaicin cream every 4 h. Topical anesthetic such as EMLA or 5% lidocaine patch for allodynia. Nerve block to area of allodynia. Analgesics.

Papova virus :

Human papilloma virus (HPV)

- Virus DNA, tanpa envelope (resisten thd antiseptik,dll), tumbuh lambat
- Menginfeksi sel epitel kulit dan mukosa
- Penularan melalui kontak langsung dengan lesi penderita
- Virus masuk mukosa, kulit → menginfeksi sel epitel (keratinosit di lapisan basal epidermis) → sel hiperproliferasi → papul, plak hiperkeratotik



▲ **FIGURE 196-13** Verruca vulgaris. The process is one of extensive hyperplasia, and the hyperplastic cells contain both intranuclear and intracytoplasmic inclusion bodies.

Disease	Associated HPV Types
Plantar warts	1, * 2, † 4, 63
Myrmecia	60
Common warts	1, * 2, * 4, 26, 27, 29, 41, † 57, 65, 77
Common warts of meat handlers	1, 2, * 3, 4, 7, * 10, 28
Flat warts	3, * 10, * 27, 38, 41, † 49, 75, 76
Intermediate warts	10, * 26, 28
Epidermodysplasia verruciformis	2, * 3, * 5, * † 8, * 9, * 10, * 12, * 14, * † 15, * 17, * † 19, 20, † 21, 22, 23, 24, 25, 36, 37, 38, † 47, 50
Condyloma acuminatum	6, * 11, * 30, † 42, 43, 44, 45, † 51, † 54, 55, 70

Intraepithelial neoplasias

Unspecified	30, [†] 34, 39, [†] 40, 53, 57, 59, 61, 62, 64, 66, [†] 67, 69, 71
Low-grade	6,* 11,* 16, [†] 18, [†] 31, [†] 33, [†] 35, [†] 42, 43, 44, 45, [†] 51, [†] 52, [†] 74
High-grade	6, 11, 16, ^{*†} 18, ^{*†} 31, [†] 33, [†] 34, 35, [†] 39, [†] 42, 44, 45, [†] 51, [†] 52, [†] 56, [†] 58, [†] 66, [†]
Bowen's disease	16, ^{*†} 31, [†] 34
Bowenoid papulosis	16, ^{*†} 34, 39, [†] 42, 45, [†] 55
Cervical carcinoma	16, ^{*†} 18, ^{*†} 31, [†] 33, [†] 35, [†] 39, [†] 45, [†] 51, [†] 52, [†] 56, [†] 58, [†] 66, [†] 68, 70
Laryngeal papillomas	6,* 11*
Focal epithelial hyperplasia of Heck	13,* 32*
Conjunctival papillomas	6,* 11,* 16 ^{*†}
Others	6, 11, 16, [†] 30, [†] 33, [†] 36, 37, 38, [†] 41, [†] 48, [†] 60, 72, 73

Klinis

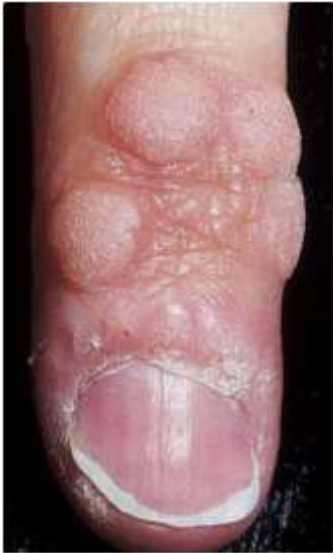Veruka Kutan

- Ditemukan lesi kulit tunggal atau berkelompok, bersisik, memiliki permukaan kasar berupa papul atau nodul yang seperti duri. Lesi muncul secara perlahan dan dapat bertahan dengan ukuran kecil, atau membesar. Lesi dapat menyebar ke bagian tubuh lain.¹
- Berdasarkan morfologinya, veruka diklasifikasikan menjadi¹:
 - Veruka vulgaris: berbentuk papul verukosa yang keratotik, kasar, dan bersisik. Lesi dapat berdiameter kurang dari 1 mm hingga lebih dari 1 cm dan dapat berkonfluens menjadi lesi yang lebih lebar.^{1,5}
 - Veruka filiformis: berbentuk seperti tanduk
 - Veruka plana: papul yang sedikit meninggi dengan bagian atas yang datar, biasanya memiliki skuama yang sedikit.
- Berdasarkan lokasi anatominya, veruka diklasifikasikan menjadi¹:
 - Veruka palmar dan plantar: lesi berupa papul hiperkeratotik, tebal dan endofitik yang terkadang disertai rasa nyeri dengan penekanan.
 - Veruka mosaik: veruka plantar atau palmar yang meluas membentuk plak
 - *Butcher's wart*: papul verukosa yang biasanya multipel pada palmar, periungual, dorsal palmar dan jari dari tukang potong daging.

Veruka Mukosa

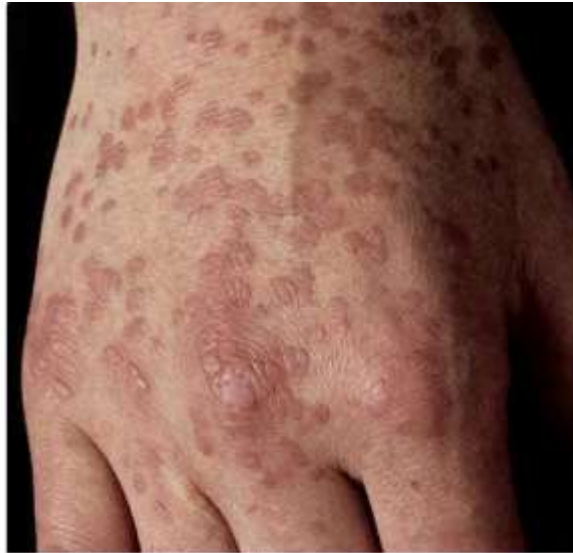- Lesi umumnya kecil, berupa papul lunak, berwarna merah muda atau putih.¹
- Biasanya ditemukan di gusi, mukosa labial, lidah, atau palatum durum. Terkadang dapat pula muncul di uretra dan dapat menyebar ke kandung kemih. Dapat disebabkan karena kontak seksual.¹

Papovavirus : Human papilloma virus (HPV)



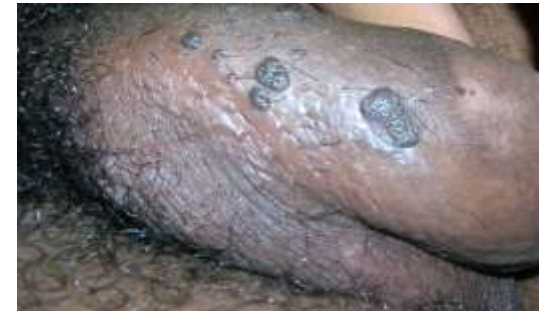Copyright ©2006 by The McGraw-Hill Companies, Inc.
All rights reserved.

Veruka vulgaris



Copyright ©2006 by The McGraw-Hill Companies, Inc.
All rights reserved.

Veruka plana



Kondiloma akuminata

Papovavirus : Human papilloma virus (HPV)

Terapi

Goal	Aggressive therapies, which are often quite painful and may be followed by scarring, are usually to be avoided because the natural history of cutaneous HPV infections is for spontaneous resolution in months or a few years. Plantar warts that are painful because of their location warrant more aggressive therapies.
Patient-initiated therapy	Minimal cost; no/minimal pain.
For small lesions	10–20% salicylic acid and lactic acid in collodion.
For large lesions	40% salicylic acid plaster for 1 week, then application of salicylic acid–lactic acid in collodion.
Imiquimod cream	At sites that are not thickly keratinized, apply half-strength 3 times per week. Persistent warts may require occlusion. Hyperkeratotic lesions on palms/soles should be debrided frequently; Imiquimod used alternately with a topical retinoid such as tazarotene topical gel may be effective.
Hyperthermia for verruca plantaris	Hyperthermia with hot water (113°F) immersion for 1/2 to 3/4 h two or three times weekly for 16 treatments is effective in some patients.

Terapi

Clinician-initiated therapy

Costly, painful.

Cryosurgery

If patients have tried home therapies and liquid nitrogen is available, light cryosurgery using a cotton-tipped applicator or cryospray, freezing the wart and 1 to 2 mm of surrounding normal tissue for approximately 30 s, is quite effective. Freezing kills the infected tissue but not HPV. Cryosurgery is usually repeated about every 4 weeks until the warts have disappeared. Painful.

Electrosurgery

More effective than cryosurgery, but also associated with a greater chance of scarring. EMLA cream can be used for anesthesia for flat warts. Lidocaine injection is usually required for thicker warts, especially palmar/plantar lesions.

CO₂ laser surgery

May be effective for recalcitrant warts, but no better than cryosurgery or electrosurgery in the hands of an experienced clinician.

Surgery

Single, nonplanar verruca vulgaris: curettage after freon freezing; surgical excision of cutaneous HPV infections is not indicated in that these lesions are epidermal infections.

Terapi

Clinician-initiated therapy

Costly, painful.

Cryosurgery

If patients have tried home therapies and liquid nitrogen is available, light cryosurgery using a cotton-tipped applicator or cryospray, freezing the wart and 1 to 2 mm of surrounding normal tissue for approximately 30 s, is quite effective. Freezing kills the infected tissue but not HPV. Cryosurgery is usually repeated about every 4 weeks until the warts have disappeared. Painful.

Electrosurgery

More effective than cryosurgery, but also associated with a greater chance of scarring. EMLA cream can be used for anesthesia for flat warts. Lidocaine injection is usually required for thicker warts, especially palmar/plantar lesions.

CO₂ laser surgery

May be effective for recalcitrant warts, but no better than cryosurgery or electrosurgery in the hands of an experienced clinician.

Surgery

Single, nonplanar verruca vulgaris: curettage after freon freezing; surgical excision of cutaneous HPV infections is not indicated in that these lesions are epidermal infections.

Penatalaksanaan

Pencegahan

1. Mengurangi risiko transmisi, seperti menutup kutil dengan bahan tahan air ketika berenang, menghindari pemakaian barang pribadi secara bersama-sama, dan menggunakan alas kaki ketika menggunakan toilet umum.⁸
2. Mengurangi risiko auto-inokulasi, seperti tidak menggaruk lesi, tidak menggigit kuku, dan tidak mencukur daerah yang terdapat kutil.⁸

Medikamentosa

Terdapat beberapa obat/tindakan yang dapat dipilih sesuai dengan indikasi sebagai berikut:

1. Agen destruktif
 - Asam salisilat⁹ (B,1)
 - Fenol liquefaktum 80%¹⁰ (C,3)
 - Kantaridin¹¹ (C,4)
 - Asam trikloroasetat & asam monokloroasetat¹² (C,3)
 - Perak nitrat 10%¹³ (C,3)
 - Asam format¹⁴ (C,3)
2. Agen virusidal
*Glutaraldehyde*¹⁵ (C,4)
3. Agen antiproliferasi
 - Krim 5-florourasil 5%^{16**} (C,1)
 - *Topical retinoids*¹⁷ (C,4)
4. Terapi imunologi
Imiquimod^{9**} (D,1)

5. Terapi intralesi

Antiproliferative agents

- Lima-florourasil, lidokain, dan epinefrin¹⁸ (C,1)
- *Bleomycin*⁹ (C,1)
- Interferon beta⁹ (C,1)

6. Terapi oral

- Zinc oral¹⁹ (C.1)
- Antagonis reseptor histamin-2²⁰ (D,1)

Catatan : **Menunggu persetujuan Badan Pengawas Obat dan Makanan Indonesia

Tindakan

1. Bedah beku²¹ (B,1)
2. Bedah laser⁹ (C,1)
3. Bedah pisau¹ (C,4)
4. *Photodynamic therapy*⁹ (C,1)

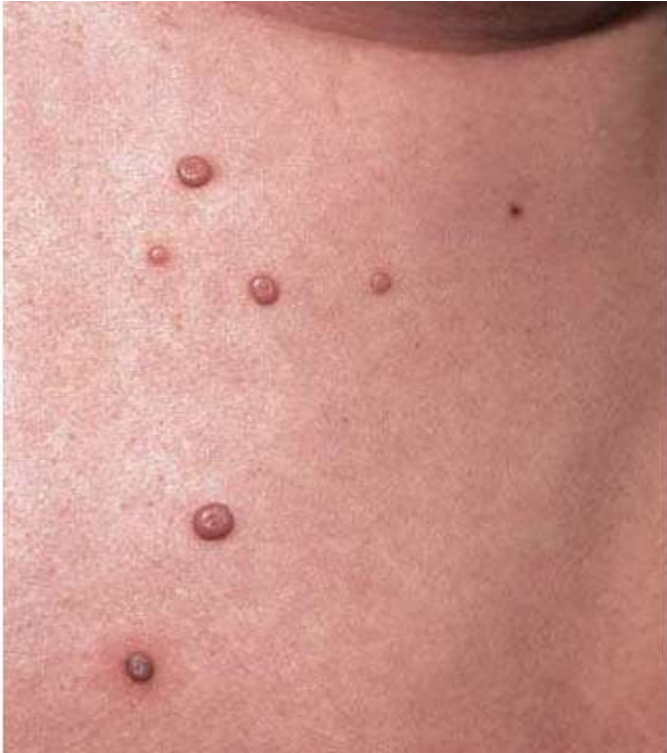Edukasi^{1,2}

1. Penyakit dan penyebabnya^{1,3}:
 - Umumnya kutil dapat hilang spontan tanpa pengobatan
 - Kutil dapat mengalami rekurensi
 - Kurangi kontak dengan lesi karena dapat meningkatkan risiko penularan ke bagian tubuh yang lain
 - Jangan mencoba untuk mencabut lesi
2. Cara pencegahan
3. Pilihan terapi dan efek samping

Poxvirus :

Virus Molluscum Contagiosum

- Virus DNA, replikasi di sitoplasma
- Penularan melalui kontak langsung dengan lesi penderita.
- Anak-anak, usia reproduktif, laki-laki lbh banyak.
- Virus masuk sel epidermis → **proliferasi sel epidermal dengan eosinophilic inclusion bodies (Guarnieri bodies) → papul umbilicated 1-2 mm, dengan moluskum bodies**
- Wajah, leher, badan (aksila), anogenital
- Sembuh spontan dalam 6 bulan, tanpa rasa nyeri, gatal +/-



Gb. Kasus Moluscum kontagiosum.
Tampak papul sewarna kulit, sebagian eritem, dengan umbilikasi (cekung bagian tengah), multipel, tersebar.

Poxvirus :

Virus Molluscum Contagiosum

Prevention	Avoid skin-to-skin contact with individual having mollusca. HIV-infected individuals with mollusca in the beard area should be advised to minimize shaving facial hair or grow a beard.
Supportive therapy	In immunocompetent children and sexually active adults, mollusca regress spontaneously; painful aggressive therapy is not indicated.
Treatment of lesions	
Topical patient-directed therapy	5% imiquimod cream applied hs 3 times per week for up to 1–3 months.
Clinician-directed therapy (office)	These procedures are painful and traumatic, especially for young children. EMLA cream applied to lesions 1 h before therapy reduces/eliminates pain.
Curettage	Small mollusca can be removed with a small curette with little discomfort or pain.
Cryosurgery	Freezing lesions for 10–15 s is effective and minimally painful, using either a cotton-tipped applicator or liquid nitrogen spray.
Electrodesiccation	For mollusca refractory to cryosurgery, especially in HIV-infected individuals with numerous and/or large lesions, electrodesiccation or laser surgery is the treatment of choice. Large lesions usually require injected lidocaine anesthesia. Giant mollusca may require several cycles of electrodesiccation and curettage to remove the large bulk of lesions; these lesions may extend through the dermis into the subcutaneous fat.

Terapi Topikal

2. Terapi topikal:

- Kantaridin** (0,7% atau 0,9%) dioleskan pada lesi dan dibiarkan selama 3-4 jam, setelah itu dicuci. Setelah itu diberikan salep antibiotik untuk mencegah infeksi sekunder. Dapat dilakukan sebulan sekali hingga tidak ada lesi lagi^{8,11} (B,1)
- Podofilin (10%-25% dalam bentuk resin) atau (0,3% atau 0,5% dalam bentuk krim). Dioleskan pada tiap lesi 2 kali sehari selama 3 hari berturut-turut, jika lesi masih persisten hingga hari ke-7, terapi yang sama dilanjutkan selama 3 minggu^{8,12} (A,1)
- Pasta perak nitrat** 40%^{8,13} (C,4)
- Kalium hidroksida 10% 2 kali/hari selama 30 hari atau sampai terjadi inflamasi dan ulserasi di permukaan papul^{14,15}(A,1)
- Gel asam salisilat 12%^{8,16} (A,1)
- Krim adapalen 1% selama 1 bulan¹⁷ (C,4)
- *Pulsed dye laser*: untuk MK rekalsitran, tiap lesi menggunakan sinar laser 585 nm *single shot* (3 mm, 300 ms, 8,0 J/cm²)^{8,18} (C,4)
- Benzoil peroksida 10% dioleskan 2 kali sehari selama 4 minggu^{8,19} (A,1)
- Solusio povidon iodine 10% dan plester asam salisilat 50%^{8,20} (C,4)

IV. Edukasi^{1-4,7}

1. Menghindari kontak langsung.
2. Pengobatan memakan waktu lama, diperlukan ketekunan dan kesabaran.

V. Prognosis¹⁻⁴

Pada pasien imunokompeten dapat swasirna dalam 6-9 bulan tanpa meninggalkan parut, kecuali jika mengalami infeksi.⁷

Quo ad vitam : bonam

Quo ad functionam : bonam

Quo ad sanactionam : bonam

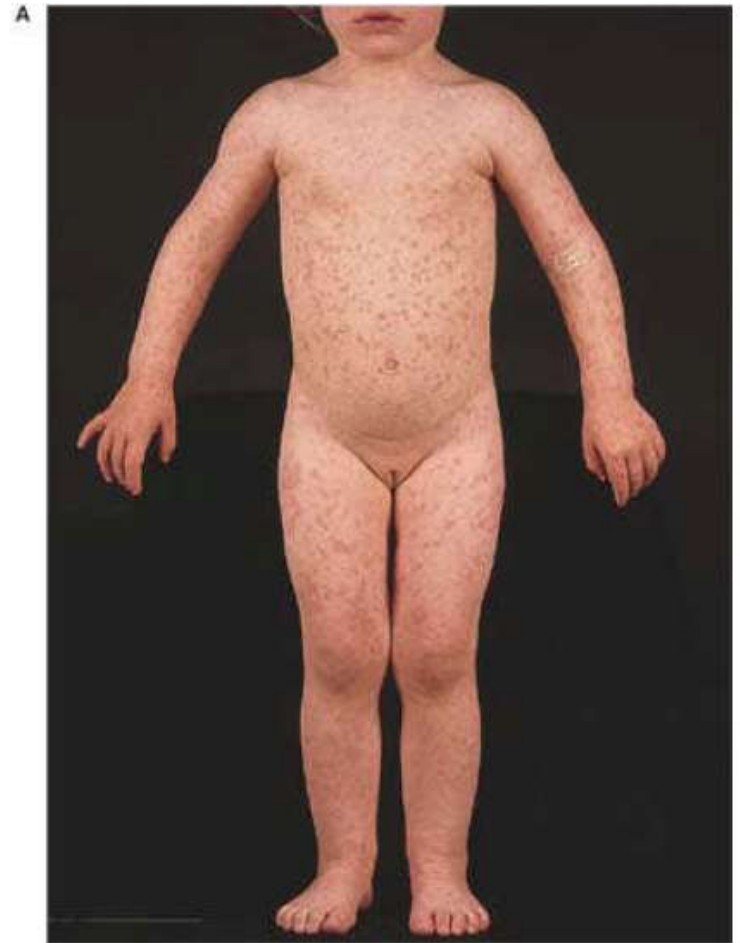Eksantema virus

- Ada berbagai jenis virus penyebab Eksantema virus, yaitu: Rubella, paramyxovirus (campak), parvovirus B19 (erytoma infeksiusum), CMV, EBV, HHV 6-7 (eksantema subitum), dll.
- Penularan penyakit melalui saluran nafas, saluran pencernaan/makanan, hubungan seksual, atau darah.
- Terbanyak mengenai anak dan remaja usia < 20 th
- Lesi kulit yang terjadi merupakan → efek langsung dari virus dan atau respon tubuh terhadap virus.
- Inkubasi < 3 bl, disertai gejala prodromal,
- Bentuk lesi kulit bervariasi, bisa scarlatiniform, morbiliform, vesikuler, atau lesi di mukosa.

Jenis/bentuk lesi pada Eksantema virus:

1. Scarlatiniform

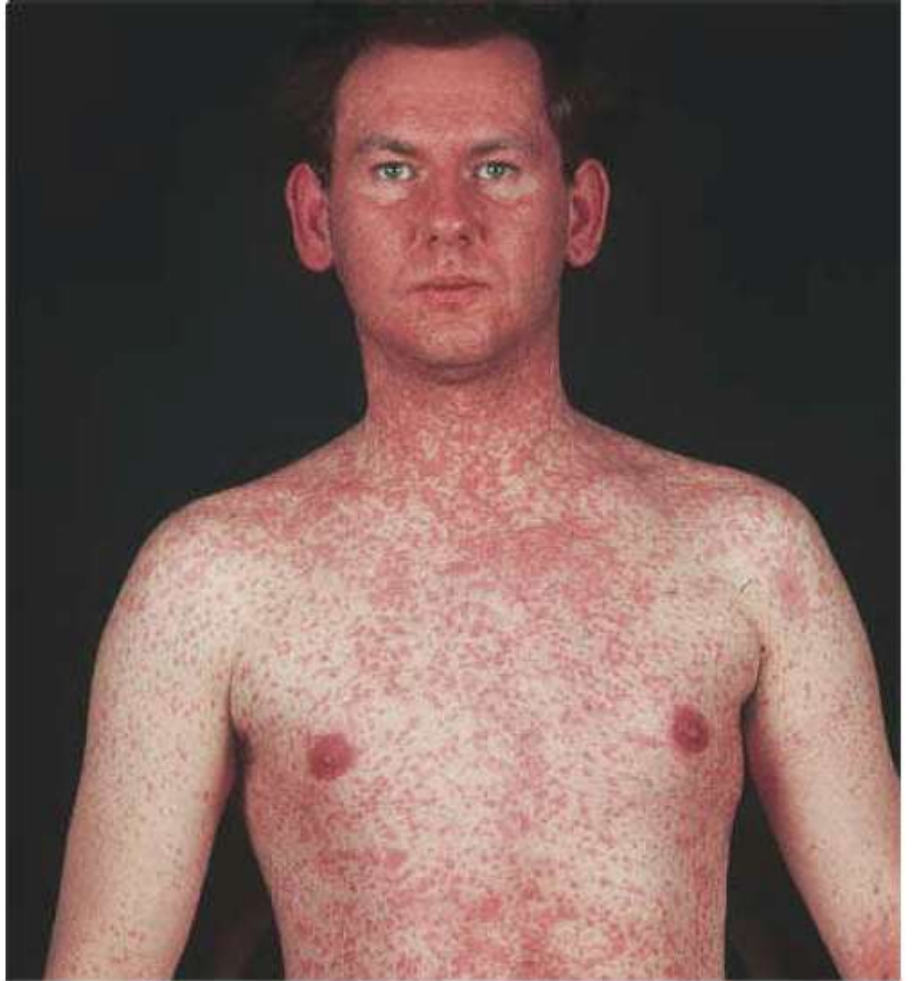Seluruh tubuh: papul eritem, multiple.



Copyright ©2006 by The McGraw-Hill Companies, Inc.
All rights reserved.

Eksantema virus

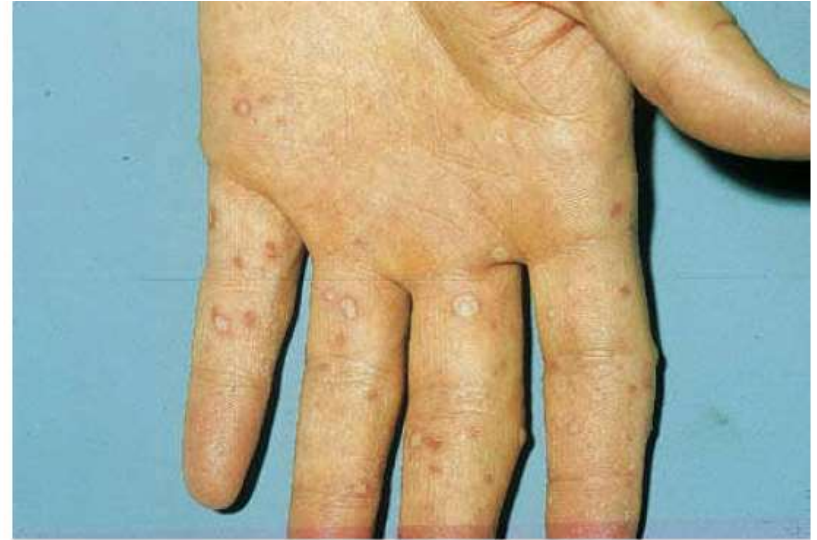2. Morbiliformis: eritem, purpurik, multipel



Copyright ©2006 by The McGraw-Hill Companies, Inc.
All rights reserved.

Eksantema virus

3. Vesikuler : vesikel atau pustul, multiple, di badan atau ekstremitas.

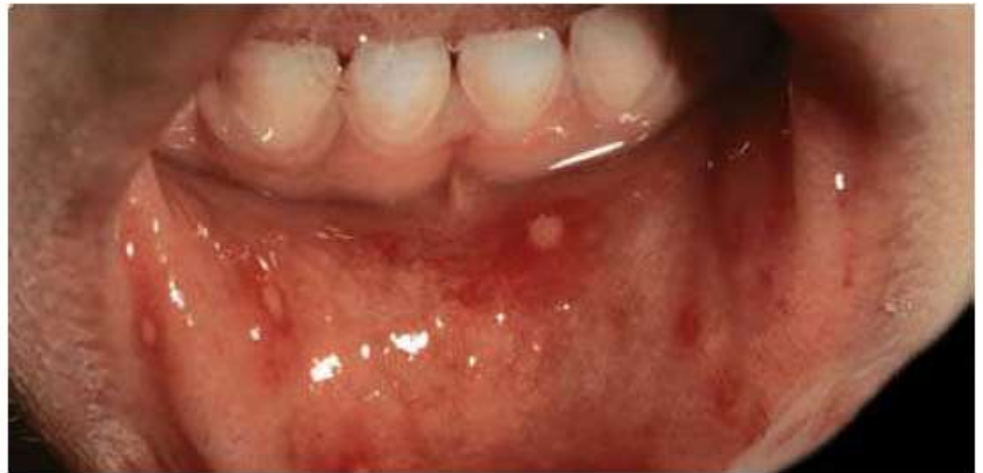

Copyright ©2006 by The McGraw-Hill Companies, Inc.
All rights reserved.

Eksantema virus

Gejala :

1. Lesi mukosa
2. Lesi kulit



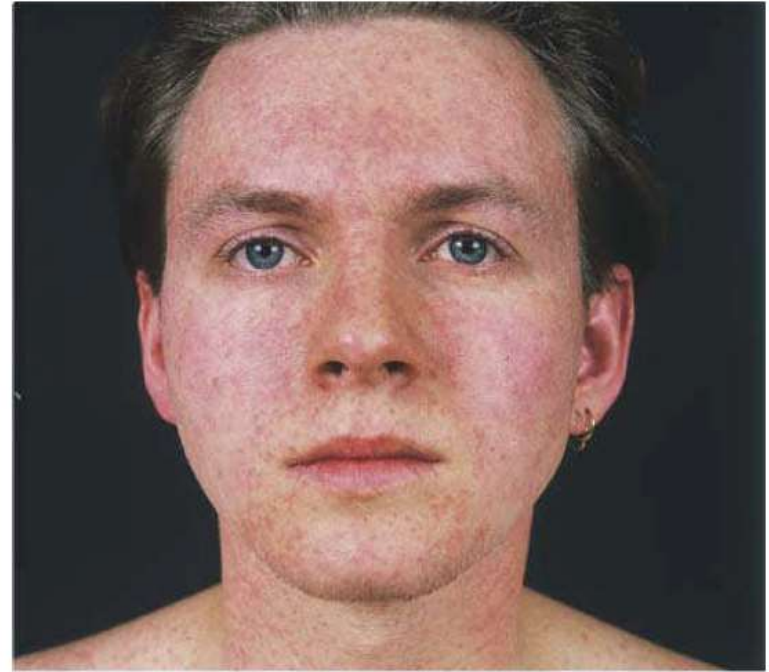Copyright ©2006 by The McGraw-Hill Companies, Inc.
All rights reserved.

Viral Exanthems

1. Rubella

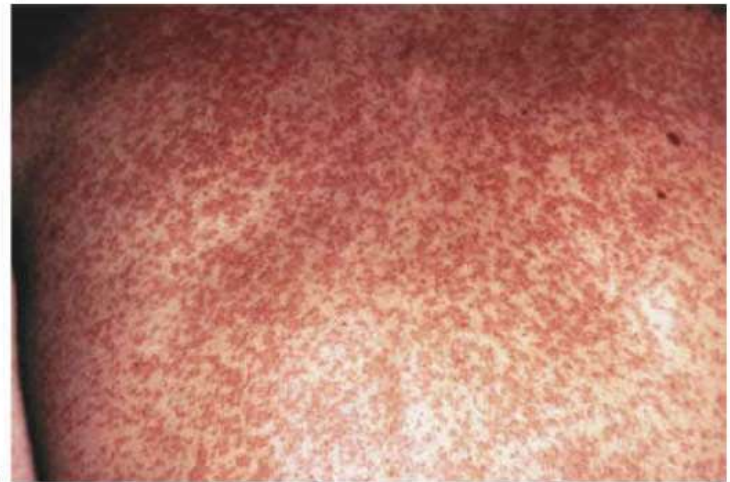= German measles

= 3-days measles



A

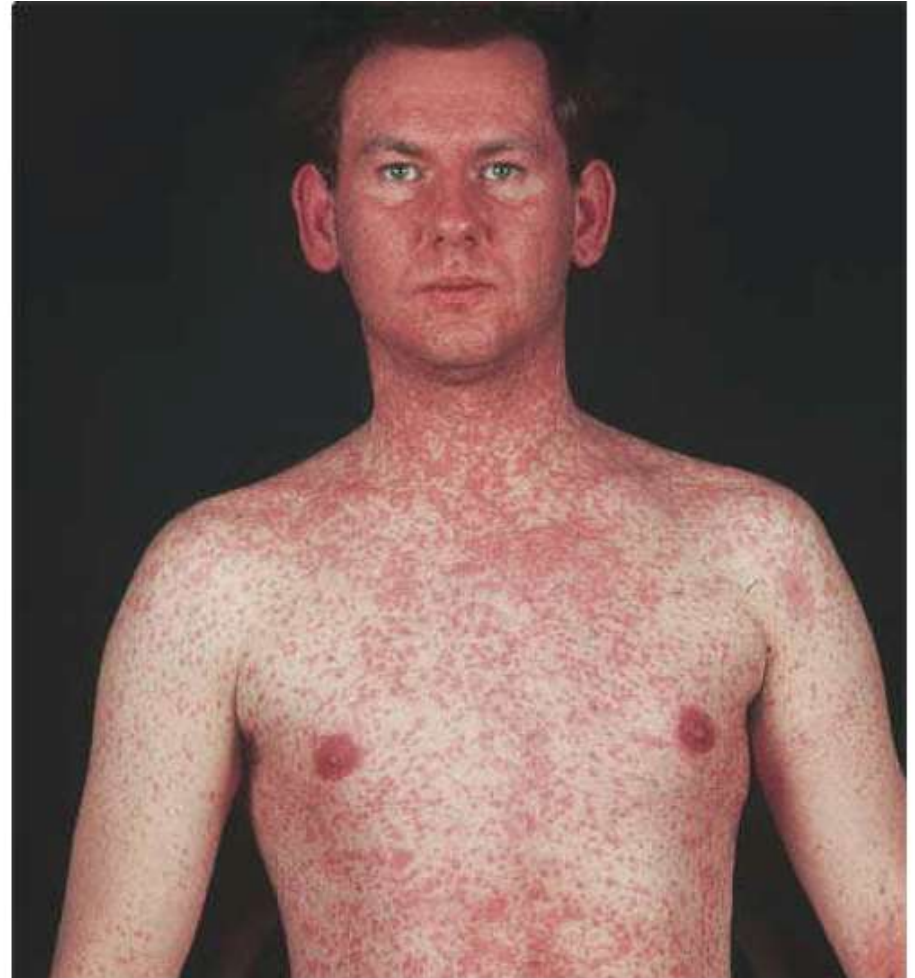Copyright ©2006 by The McGraw-Hill Companies, Inc.
All rights reserved.



B

Copyright ©2006 by The McGraw-Hill Companies, Inc.
All rights reserved.

2. Measles
=rubeola
=morbilli



Copyright ©2006 by The McGraw-Hill Companies, Inc.
All rights reserved.

Eksantema virus

Terapi

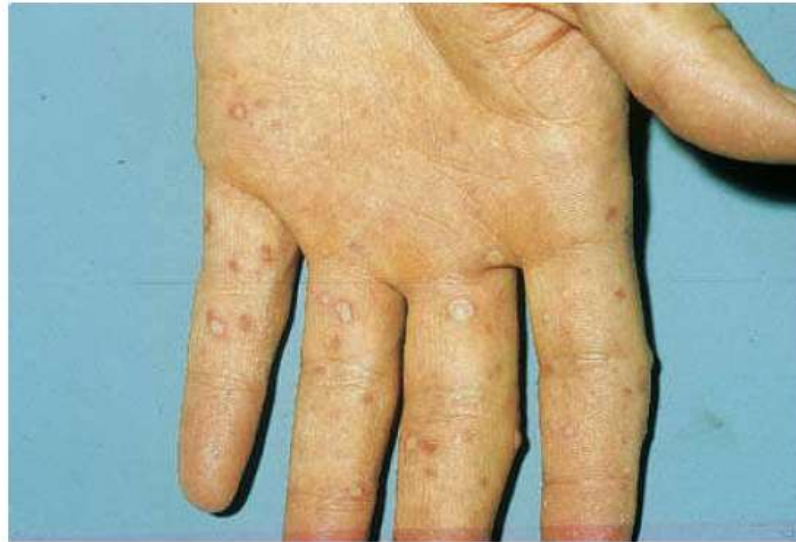- Prinsip dan tujuan terapi semua jenis eksantema virus sama, yaitu meningkatkan daya tahan tubuh, terutama imunitas humoral.
- Self healing
- Terapi simtomatik:
 - Antipiretik
 - Antihistmain
 - *Lidocaine gel* (mengurangi rasa nyeri pd mulut)

Hand-foot-and-mouth disease (HFMD)

- **Penyebab:** coxsackievirus A16, Enterovirus (picornavirus group, single-strand RNA, unenveloped). enterovirus 71. coxsackieviruses A4–7, A9, A10, B2, and B5
- **Penularan:** oral – oral; fekal - oral
- **Gejala:**
 - erosi – ulkus di oral, nyeri.
 - eksantem vesikuler pada ekstremitas distal, kadang terasa nyeri, gatal.
 - gejala sistemik (demam, lemah) ringan.

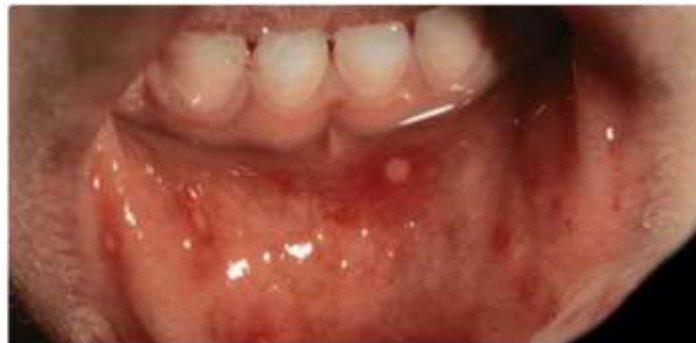Perjalanan penyakit :

- Enteroviral implantation in the GI tract (buccal mucosa and ileum) - regional lymph nodes - viremia (72 hours) - seeding of the oral mucosa and skin of the hands and feet – ulcerative oral lesions
- Incubation : 3 to 6 days
- Prodrome:
 - 12 to 24 h of low-grade fever,
 - malaise,
 - abdominal pain or respiratory symptoms.



Copyright ©2006 by The McGraw-Hill Companies, Inc.
All rights reserved.

Hand-foot-and-mouth disease Multiple, discrete, small, vesicular lesions on the fingers and palms; similar lesions were also present on the feet. Some vesicles are typically linear.



Copyright ©2006 by The McGraw-Hill Companies, Inc.
All rights reserved.

Hand-foot-and-mouth disease Multiple, superficial erosions and small, vesicular lesions surrounded by an erythematous halo on the lower labial mucosa; the gingiva is normal. In primary herpetic gingivostomatitis, which presents with similar oral vesicular lesions, a painful gingivitis usually occurs as well.

Prognosis

- Sembuh sendiri dalam waktu 7-10 hari : peningkatan antibodi dan viremia (-), beberapa kasus lebih lama.
- Tidak ada sequele, beberapa meluas ke myokarditis, meningoencephalitis, aseptic meningitis, paralytic disease.
- Infeksi Enterovirus 71 infections → CNS involvement and pulmonary edema → morbidity/mortality rates.
- Infection kehamilan trimester pertama → spontaneous abortion

selamat belajar

selamat belajar

wassalam



Do'a
penutup
majelis

**Subhaanakallohumma
wabihamdika**
asyhadu anlaa ilaaha illa
anta
astaghfiruka wa atuubu
ilaika



UMY

UNIVERSITAS
MUHAMMADIYAH
YOGYAKARTA

Unggul & Islami