



# INCISIVUS TEETH

(Individual Teeth Morphology)

Tm Dental Anatomi KG UMY

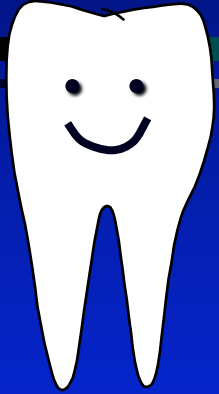


# INCISIVUS PERMANENT TEETH



- ✧ 8 teeth
- ✧ Incisivus centralis, upper and lower, right and left
- ✧ Incisivus lateralis, upper and lower, right and left

# Maxillary Incisivus Centralis



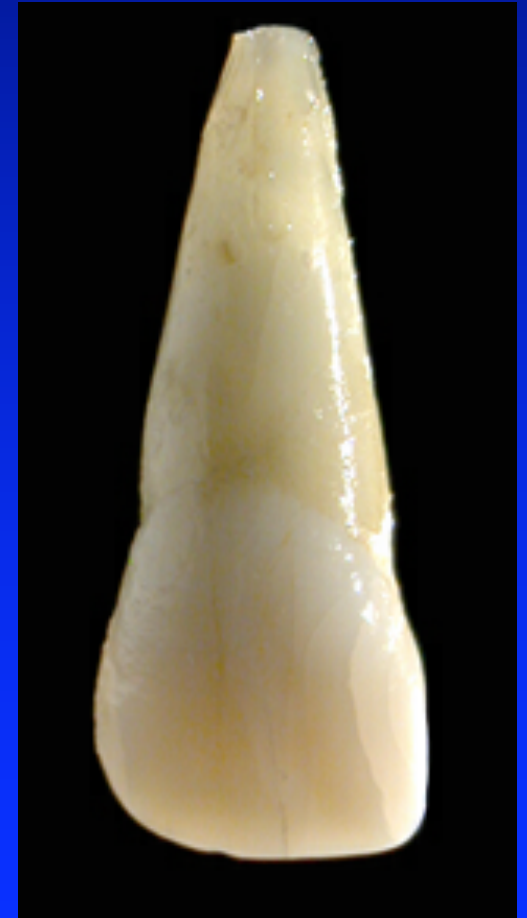- ✧ Evidence of calcification 3-4 month
- ✧ Enamel completed 4-5 years
- ✧ Eruption 7-8 years
- ✧ Root completed 10 years

# Labial aspect

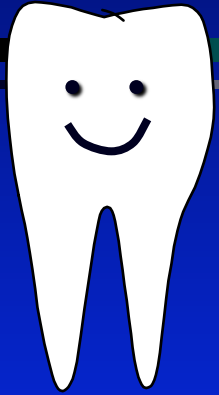


- ✦ Crown seperti sekop
- ✦ Incisal ridge → mamelon
- ✦ Disto incisal ridge, membulat/
- ✦ Mesio incisal ridge, tajam 90
- ✦ 2 sulkus, menghilang ke arah cervix
  - sulcus disto labial
  - sulcus mesio labial

membagi jadi 3 bagian →  
*triconodont*



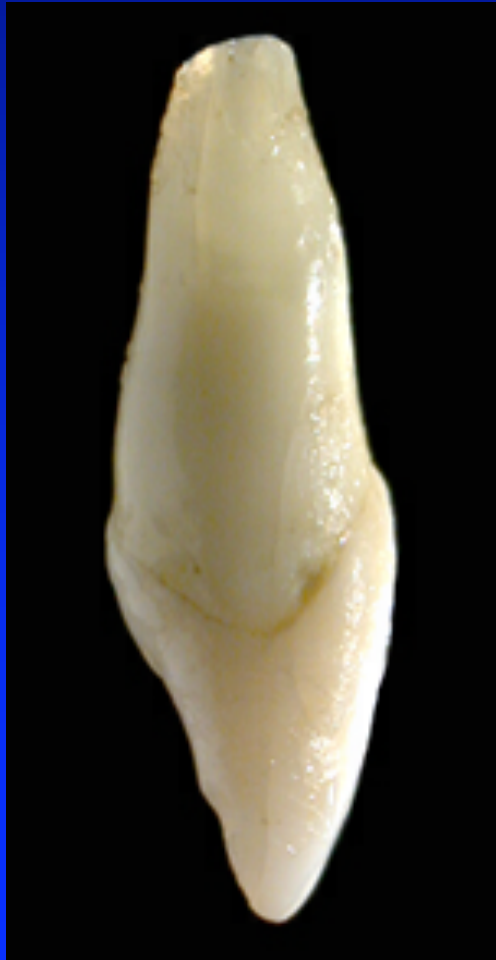
# *Palatal aspect*



- ✧ Concaf
- ✧ Fossa palatina terdapat crista mesialis dan crista distalis
- ✧ Cingulum & tuberculum di cervic

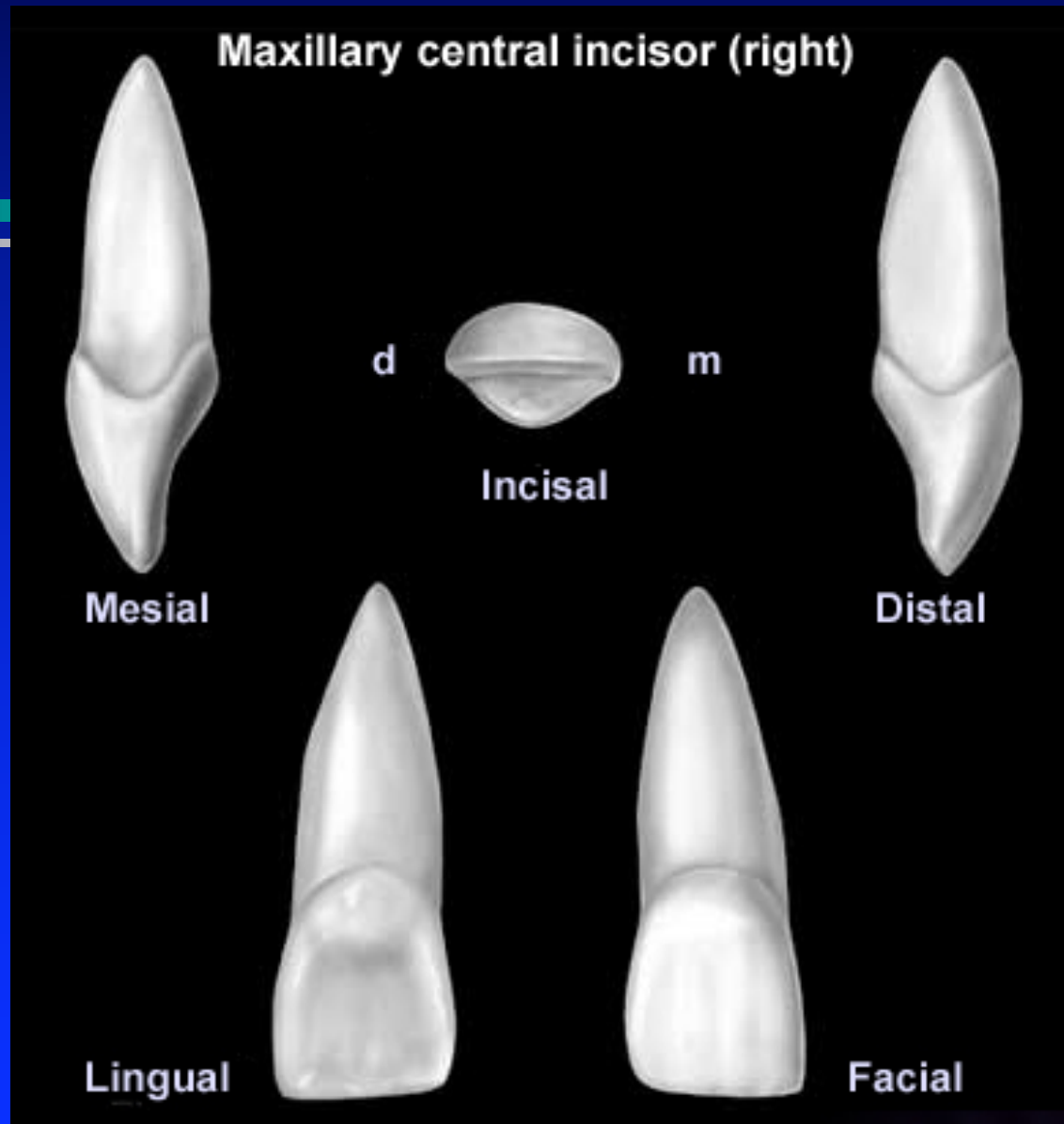



# Akar / radix




## *Akar / radix*

- ❖ Satu, pulp canal 1
- ❖ Panjang 1-1,5 kali crown
- ❖ Lurus atau bengkok ke palatinal/distal
- ❖ Bentuk seperti kerucut
- ❖ Tebal, apex bulat
- ❖ Potongan melintang berbentuk segitiga sama sisi



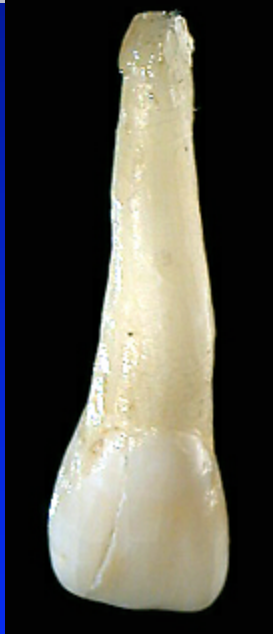# Maxillary Incisivus Lateralis



- ✦ Evidence of calcification 10 - 12 month
- ✦ namel completed 4-5 years
- ✦ Eruption 8-9 years
- ✦ Root completed 11 years

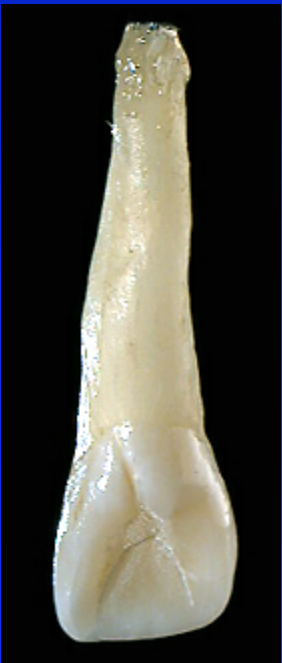

# *Labial & Palatal aspect*



## *Labial aspect*

- ✧ Lebih convec dari incisivus sentralis
- ✧ Sudut mesio incisal lancip,



## *Palatal aspect*

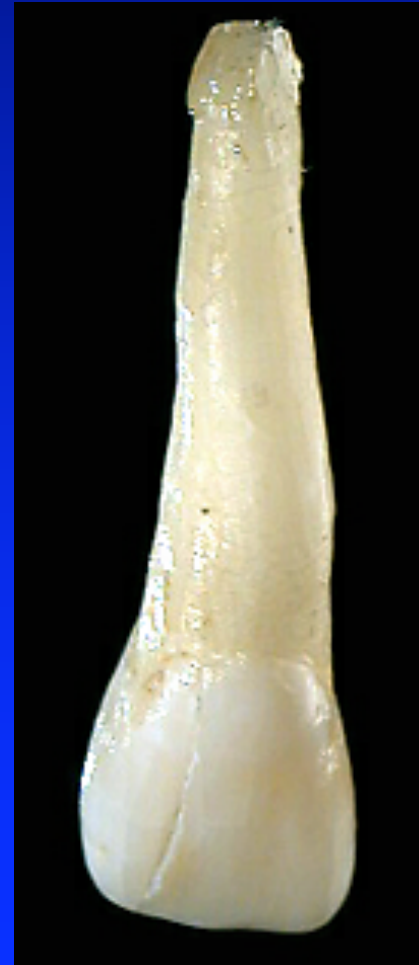- ✧ Lebih concaf dari I centralis
- ✧ Ada lingual pit
- ✧ Fossa palatinal lebih jelas
- ✧ Corak marginal ridge, huruf V

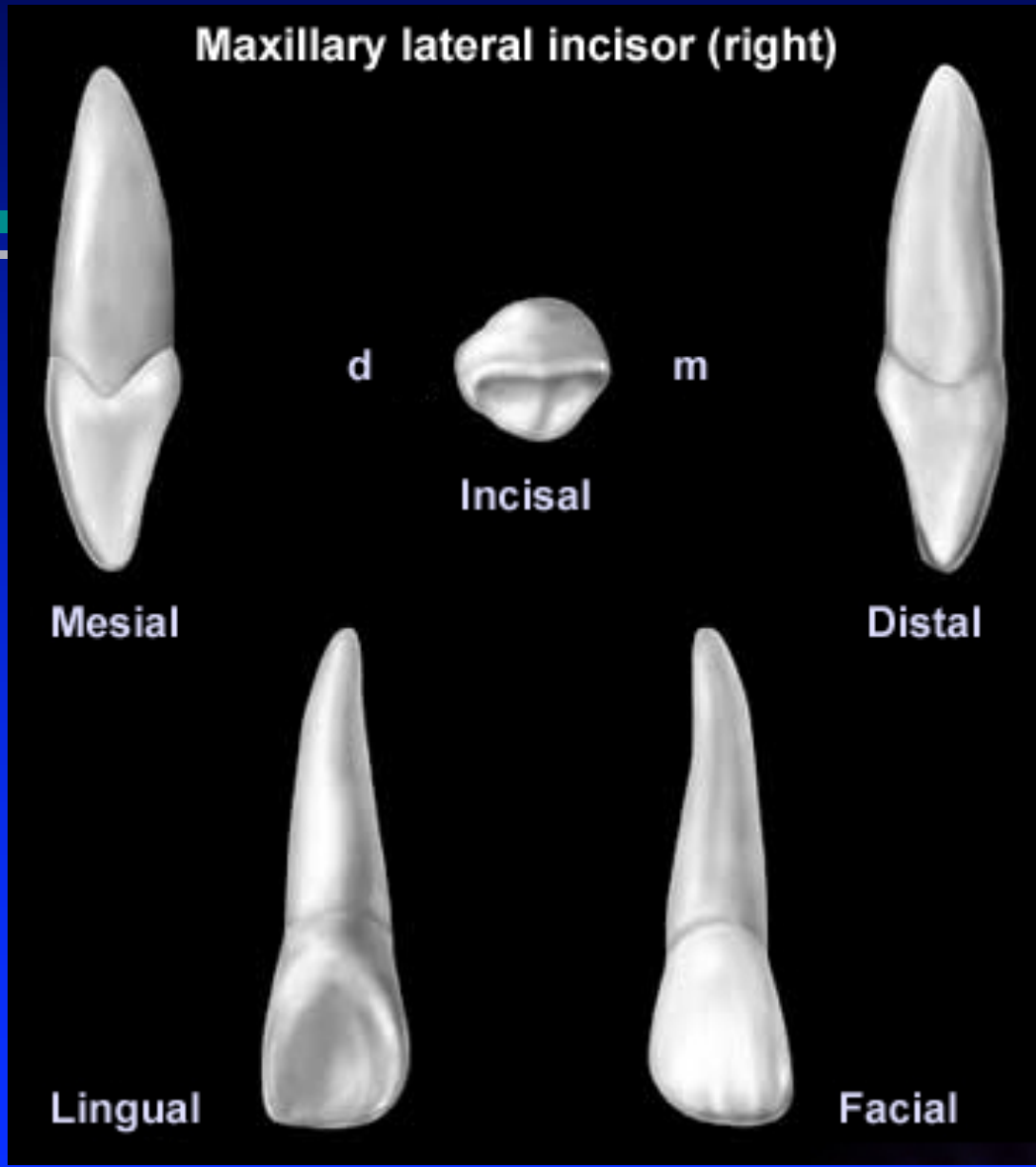

# Radix/Akar




## Radiks / akar

- ✦ Satu, panjang 1-1,5 crown
- ✦ Apex runcing, membelok ke distal
- ✦ Pulp canal 1
- ✦ Akar lebih ramping






# Mandibular Centralis Incisivus

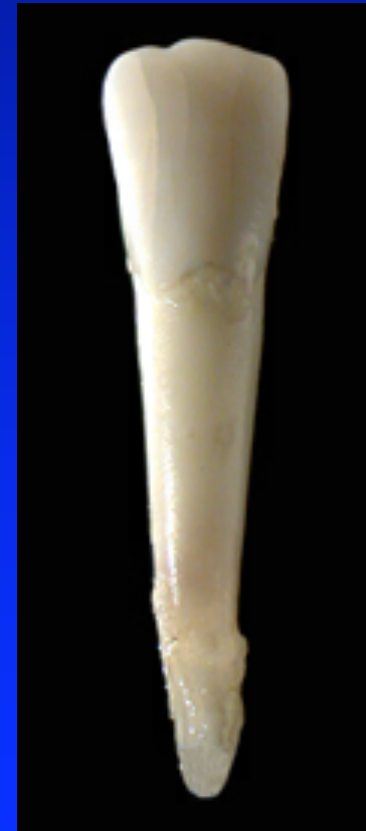

- ✧ Evidence of calcification 10 - 12 month
- ✧ namel completed 4-5 years
- ✧ Eruption 8-9 years
- ✧ Root completed 11 years

# *Labial aspect*



- ✧ Crown bentuk pahat, halus
- ✧ Mesio incisal lancip
- ✧ Disto incisal lebih bulat
- ✧ Mesio facial line angle > panjang dari disto facial line angle



# Lingual & Proximal aspect

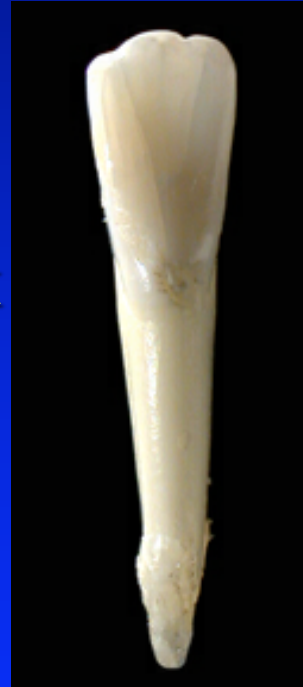

## Lingual aspect

- ✦ Cingulum amat kecil
- ✦ Tuberculum dan pit tidak ada
- ✦ Fossa lingual dangkal

## Proximal aspect

- ✦ Datar
- ✦ Berbentuk segitiga

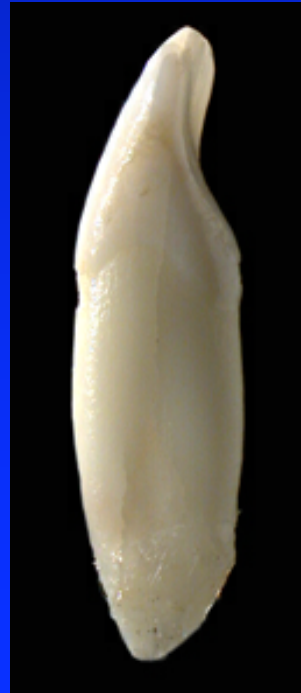

L


D



M

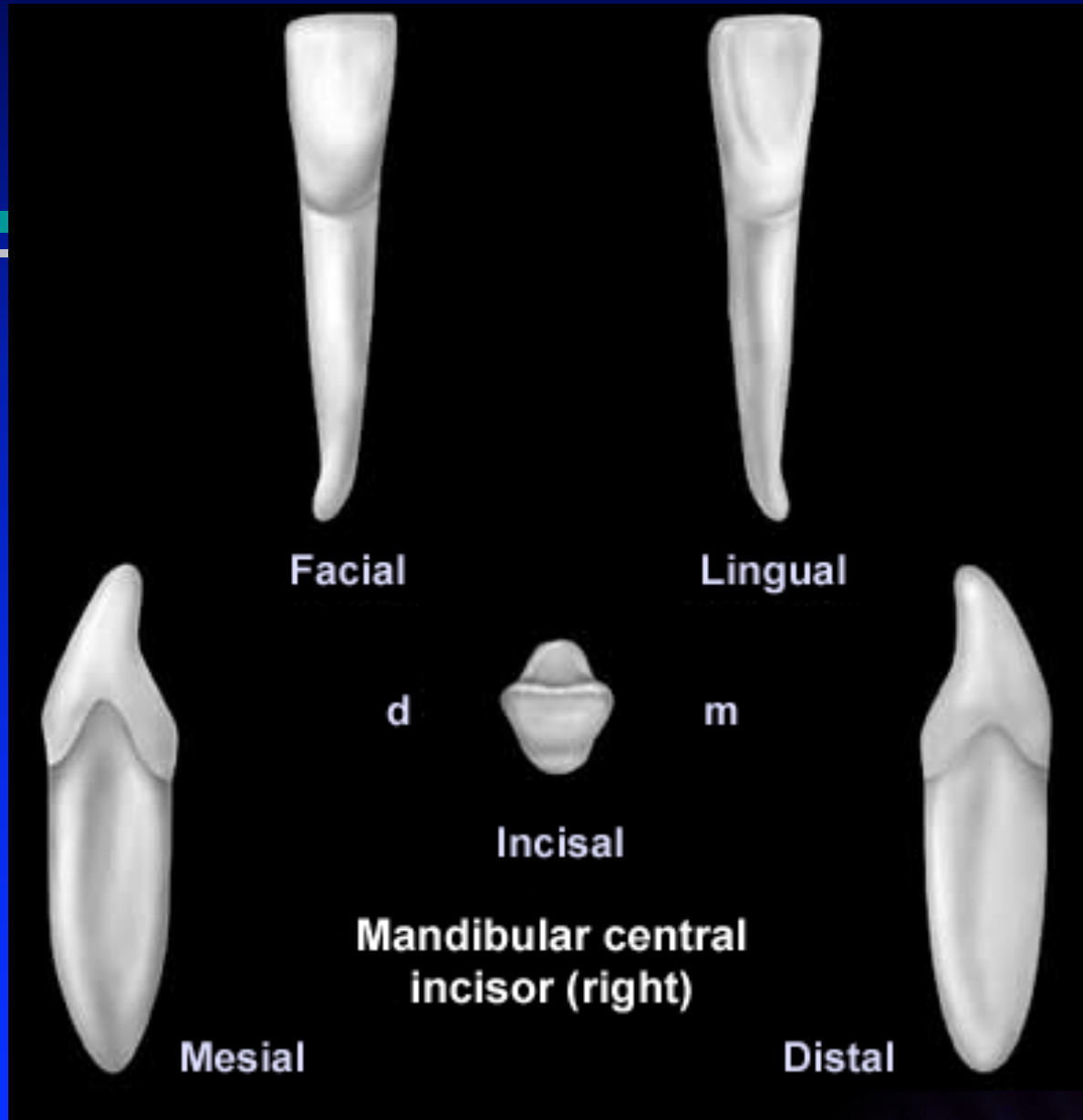



# *Radix / Akar*



## *Radix / Akar*

- ✦ Lurus dan gepeng/pipih
- ✦ Belok ke distal/labial
- ✦ Potongan melintang berbentuk oval
- ✦ Mesial distal radix ada sulcus, distal lebih jelas
- ✦ Pulp canal 1



Facial

Lingual

d

m

Incisal

Mandibular central  
incisor (right)

Mesial

Distal



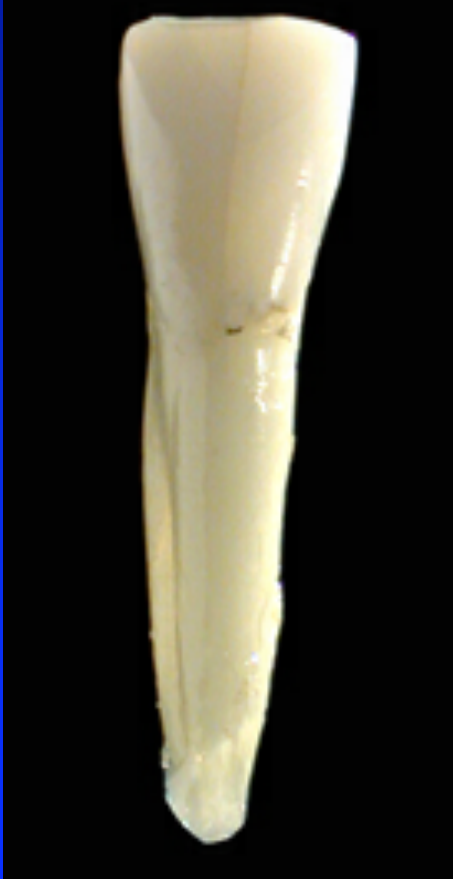
# Mandibular Lateralis Incisivus



- ✦ Evidence of calcification 3-4 month
- ✦ enamel completed 4-5 years
- ✦ Eruption 7-8 years
- ✦ Root completed 10 years

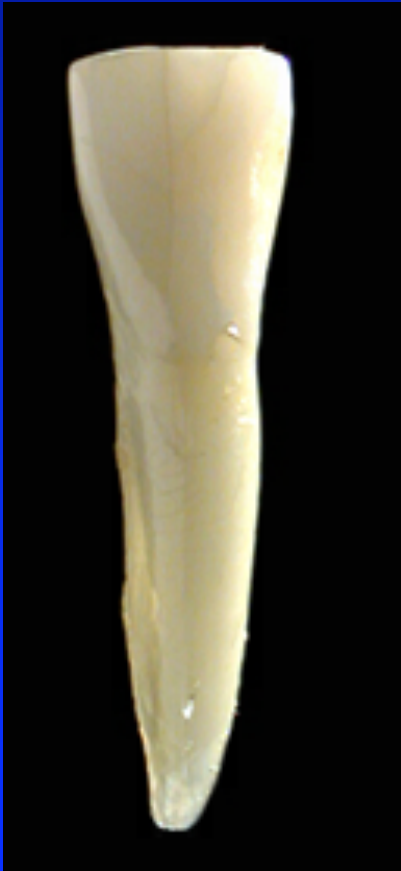Bentuk sama dengan Incisivus centralis, tetapi sedikit lebih besar dan tebal

# *Labial aspect*



- ✧ Mesial distal lebih bulat
- ✧ Mesio facial line angle  $>$  disto facila line angle
- ✧ Incisal ridge miring ke distal
- ✧ Sulcus pada labial lebih dalam dibanding incisivus centralis

# *Lingual aspect and radix*

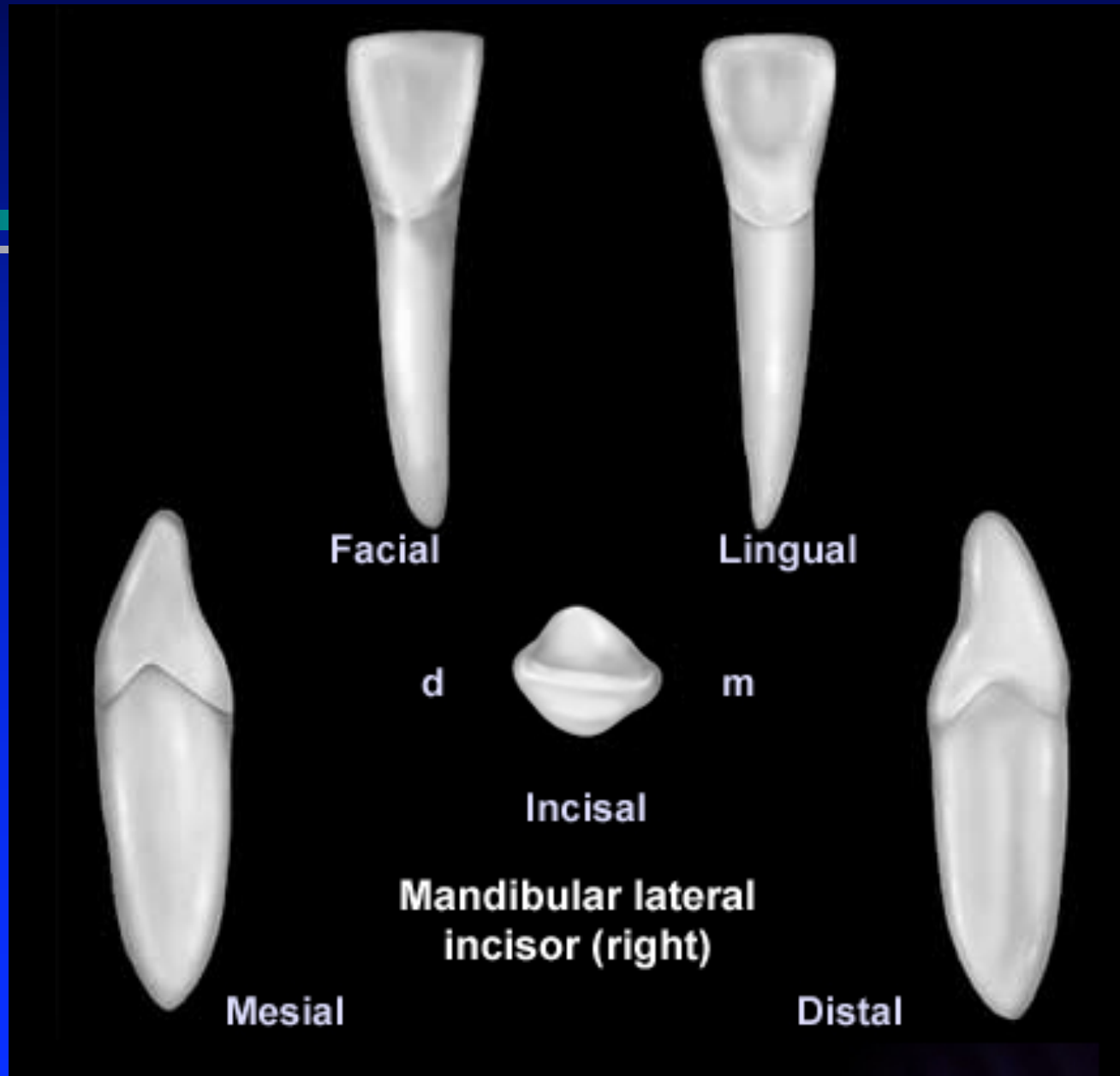



## *Lingual aspect*

- ✧ Lebih menonjol dibanding incisivus centralis
- ✧ Ridge berkembang
- ✧ Fossa kelihatan

## *Radix / Akar*

- ✧ Panjang dan pipih
- ✧ Sulcus mesial distal lebih jelas



# THANK YOU

