



CANINE MORPHOLOGY




Tim Dental Anatomi KG UMY

Maxillary Canine

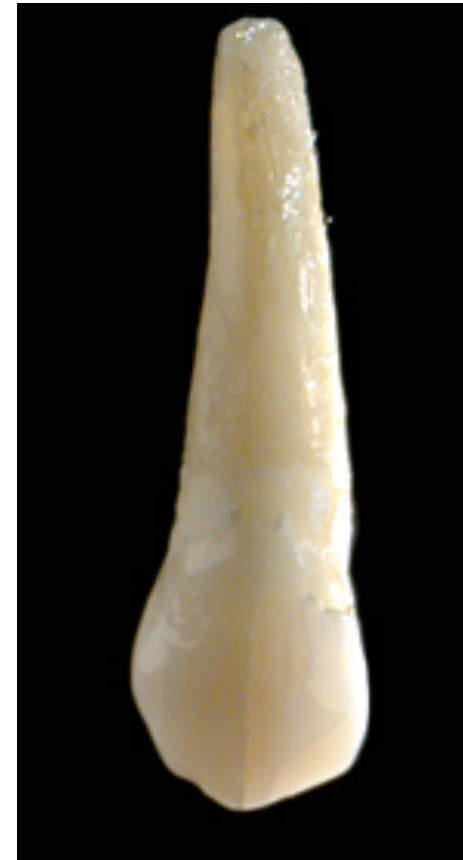

- Evidence of calcification 4-5 month
- Enamel completed 6-7 years
- Eruption 11-12 years
- Root completed 13-15 years

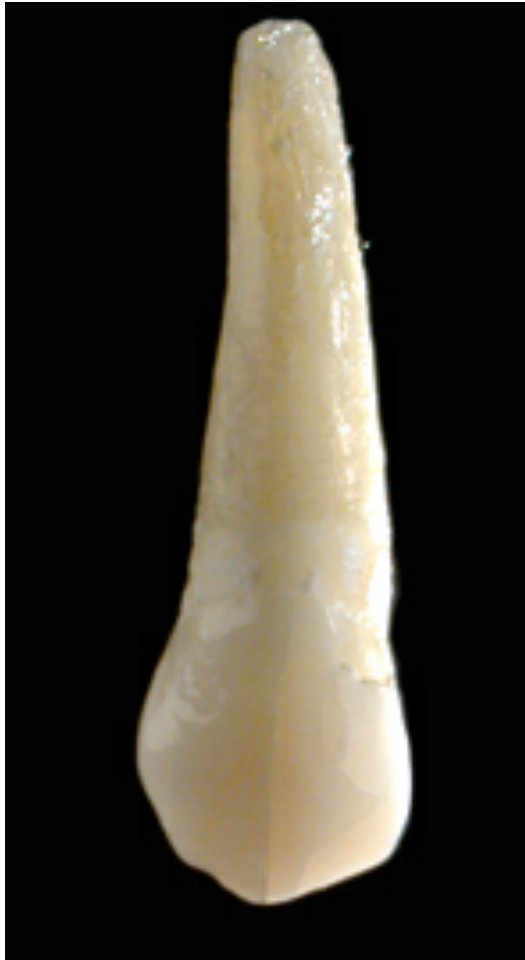
Maxillary canine, cont'



- Crown spt mata tombak
- Gigi terpanjang & gigi terkuat di anterior
- Punya 1 tonjol



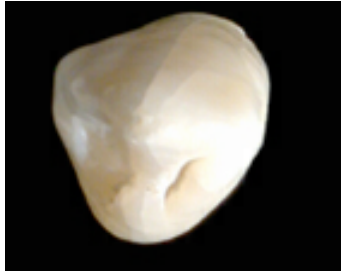
Labial aspect



- Convex
- Crista ke arah permukaan membagi facies labial jadi 2 bagian
 - Fc mesio labial (sempit, mir < dir)
 - Fc disto labial (lebar)

Mir/dir : mesio/disto incisal ridge

Incisal and proximal aspect



Incisal aspect

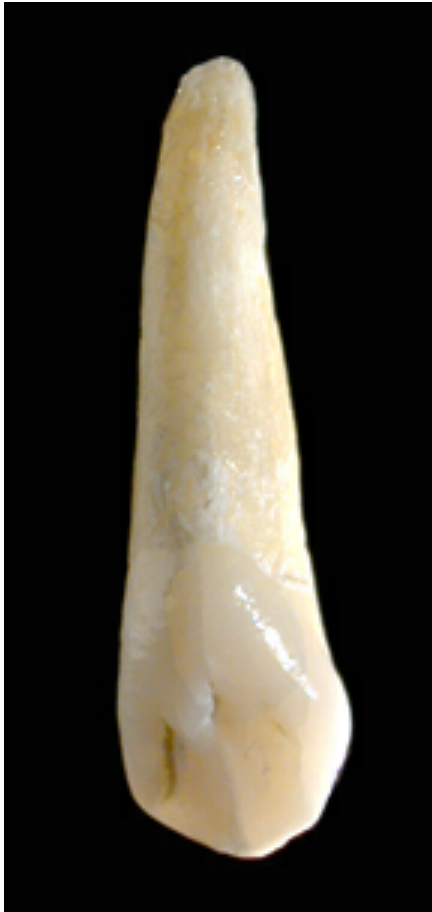
- Incisal ridge membentuk huruf V
- Bagian mesial lebih rendah
- Ujung cusp pada poros gigi



Proximal aspect


- Ujung cusp cenderung lebih ke labial dari poros gigi

Palatinal aspect

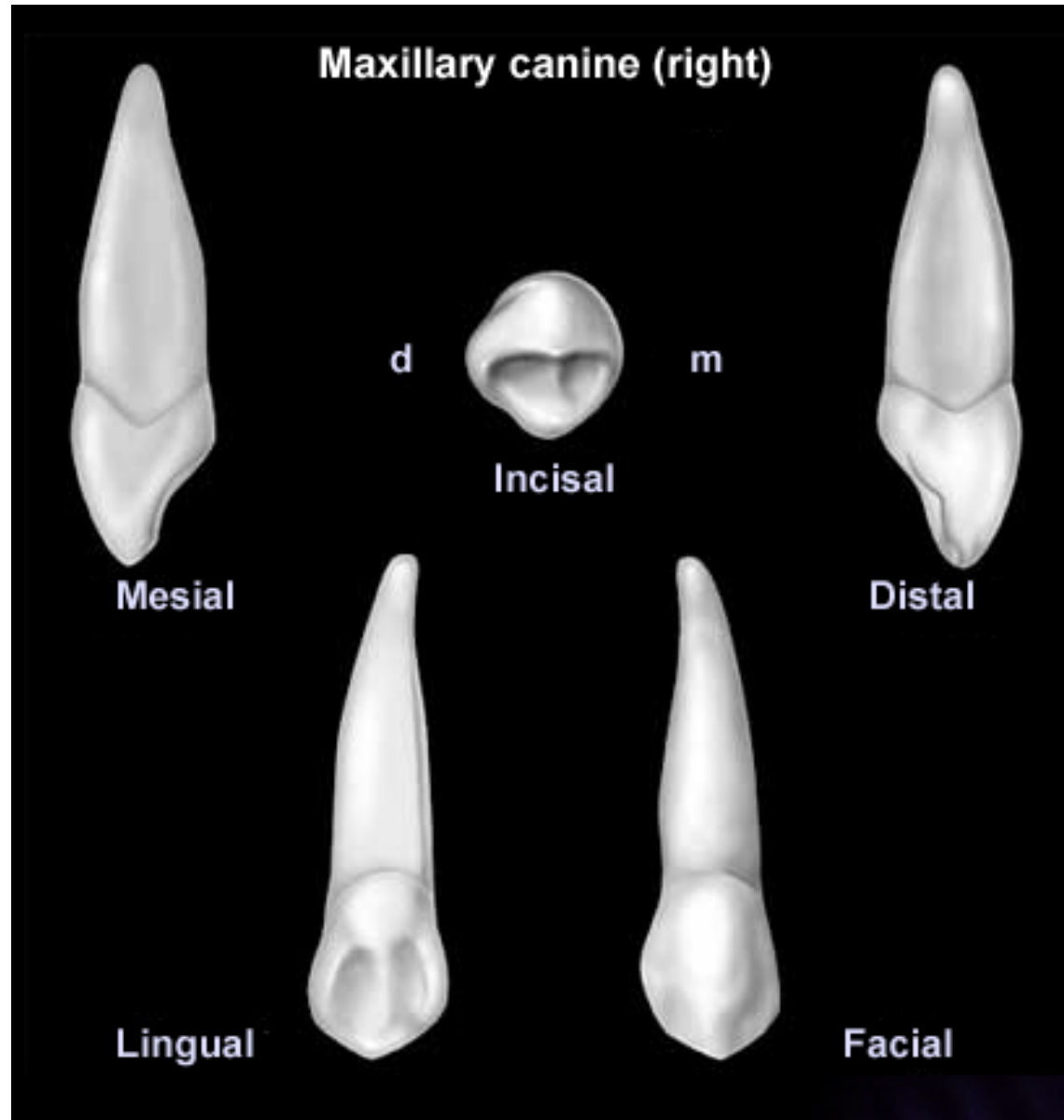



- Cingulum, tuberculum, fossa, jelas
- Fossa palatinal terbagi 2
 - Fossa mesio palatinal
 - Fossa disto palatinal
- Kedua fossa dibatasi (3 crista):
 - Crista mesialis
 - Crista palatinalis
 - Crista distalis


Radix



- Satu, panjang 2-2,5 kali pjg crown
- Canal pulp 1
- Permukaan akar sebelah mesial dan bucal ada sulcus



Mandibular Canine





- Evidence of calcification 4 month
- Enamel completed 7 years
- Eruption 9-10 years
- Root completed 13 years

Bentuk seperti upper Canine tapi lebih ramping, runcing, halus


Mahkota distal lebih membulat

Labial aspect



- Crown kelihatan panjang
- Amat convex & membelok ke arah lingual 
- **KRONENFLUCHT**
- Crista yg membagi fc labial menjadi 2 tidak jelas
- Ujung cusp lebih ke mesial dari as gigi

Proximal and Radix



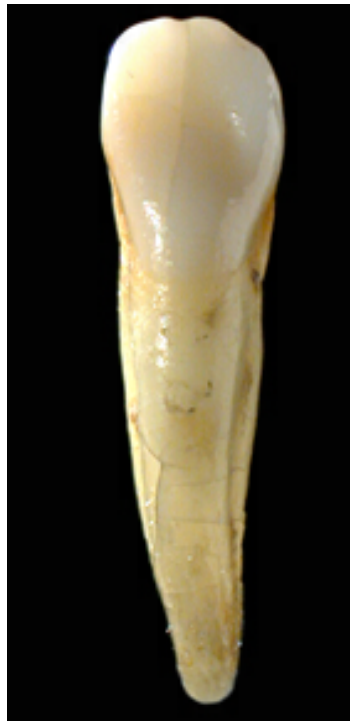
Proximal

- Puncak cusp lebih ke lingual dari as gigi

Radix

- Dibanding Canine atas lebih gepeng
- Jika membelok ke arah distal
- pul[p canal 1
- Permukaan mesial dan distal radix ada sulcus

Incisal and lingual aspect

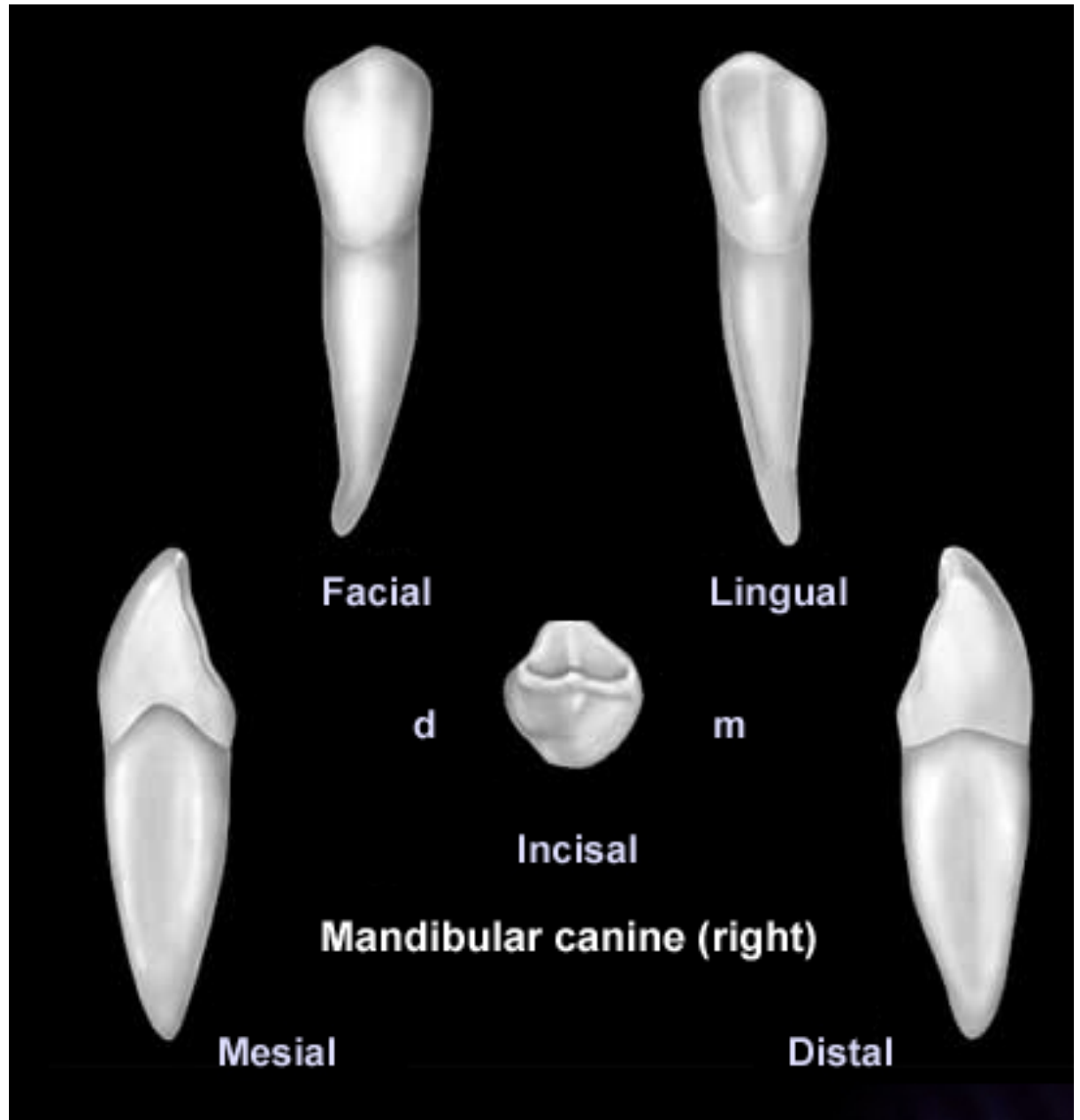




Incisal

- Incisal ridge bentuk V
- Mir lebih pendek dari dir
- Bagian distal lebih rendah dari mesial

Lingual aspect

- Cingulum tidak jelas
- Fossa, ridge kurang jelas





THANK YOU