

PEMBUKAAN BLOK 16 (ORAL SURGERY AND EMERGENCY)

TA 2022/2023

Tim Blok TA. 2022-2023



PJ : drg Indri Kurniasih, M.MedEd
08122742330



WPJ : drg Widyapramana, MDSc

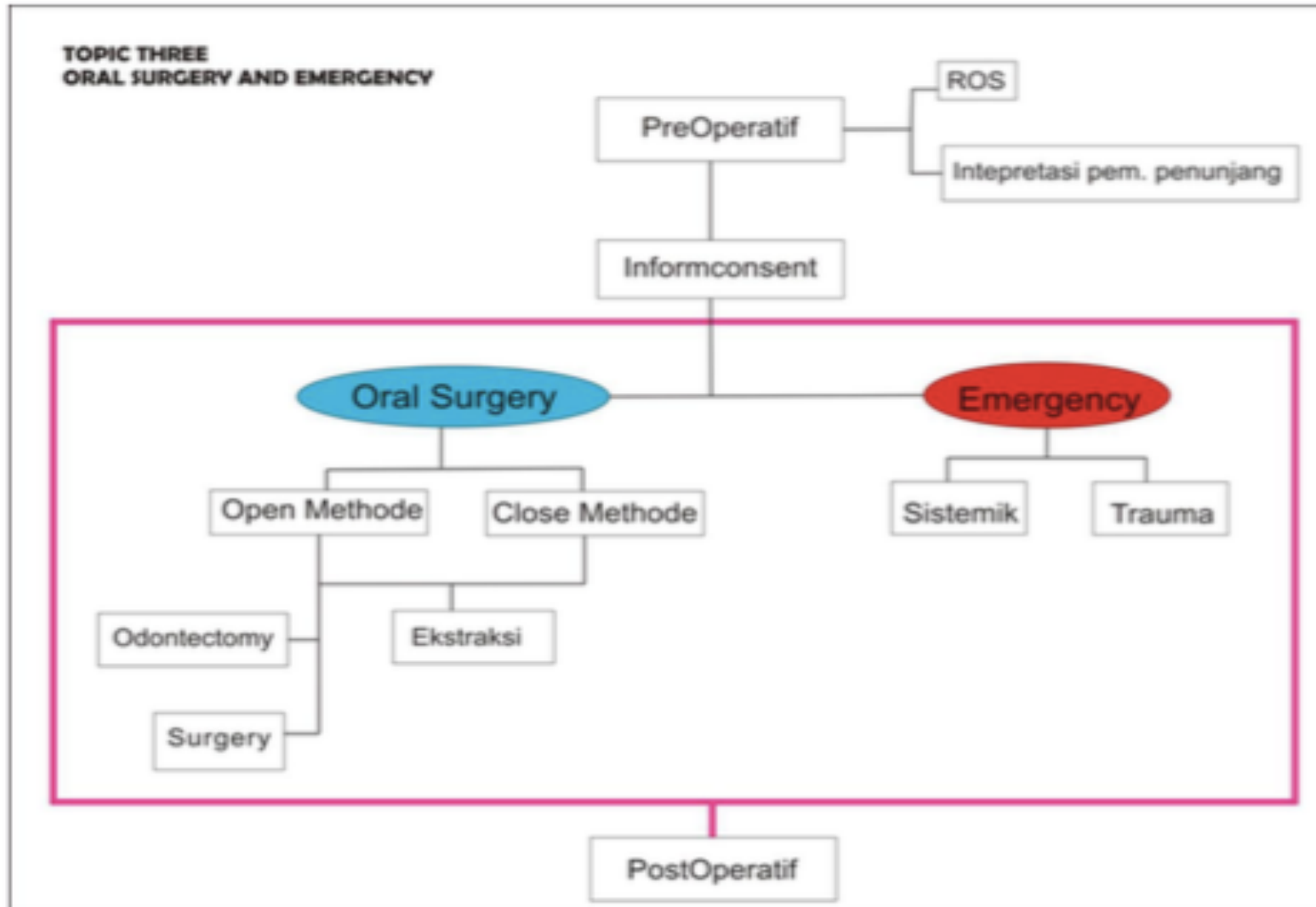


PJ Content: drg Bahrul Lutfianto, Sp. BM(K)

Deskripsi Pembelajaran Blok 16

- Blok ini berisi bahan kajian yang terkait pengetahuan dan ketrampilan dasar dalam perawatan bedah minor di rongga mulut yaitu pengetahuan dan ketrampilan yang mendasari tindakan operative, anestesi, serta pengetahuan tentang komplikasi-komplikasi yang dapat terjadi dalam perawatan bedah di rongga mulut. Pada Blok ini mahasiswa juga akan diberi bekal pengetahuan dan ketrampilan terkait tindakan penanganan kedaruratan di bidang kedokteran gigi yang sering ditemui di praktek klinik. Dimana materi tersebut merupakan salah satu materi unggulan kurikulum di Kedokteran Gigi FKIK UMY.

TOPIC TREE



Dewan Pakar :

- drg Edwyn Saleh, Sp. BMM., MARS
- drg Bahrul Lutfianto, Sp. BM (K)
- drg Atiek Driana R, MDSc., SP. KGA
- drg Indria Nehriasari, Sp. BM
- drg Driana, Sp. BM
- dr Saiful Fatah, Sp. A
- drg Erwin Setyawan, Sp. RKG
- drg Iwan Dewanto, MMR., PhD
- drg Dwi Suhartinintyas, MDSc
- Dr. dr Sagiran, Sp. B , Mkes

LEARNING CONTRACT

Sks Blok : 6.2 sks = 6 sks

Blokset	Jumlah topik
KULIAH	26 topik (Wajib hadir 75%)
Tutorial	3 PBL 3 CBL dan 1 in english (Wajib hadir 75%)
Skills lab	17 pertemuan 3 pertemuan online (SL 1 anestesi online, SL Kom, SL juring) 14 pertemuan offline 1 FST ke RSGM SL wajib hadir 100%

Mahasiswa **hadir tepat waktu** dalam tiap proses pembelajaran
SURAT IJIN KETIDAKHADIRAN DITUJUKAN LANGSUNG KEPADA PJ BLOK

Catatan kegiatan tutorial (minimal 75% kehadiran)

- Pada pertemuan ke 2 scenario PBL mahasiswa wajib membuat resume jurnal EBD terkait dan membawa saat pertemuan ke 2 untuk menjadi bahan diskusi (tidak perlu upload di MyKlass)
- **Tugas pengganti ketidakhadiran dalam scenario bahasa indonesia** atas ijin PJ Blok: membuat rekaman presentasi singkat dalam bahasa indonesia (5 slide PPT) terkait resume sebuah jurnal EBD sesuai topik tutorial yang ditinggalkan (diupload ke MyKlass blok 16)
- **Tugas pengganti ketidakhadiran dalam tutorial in english** atas ijin PJ Blok : membuat rekaman presentasi singkat dalam bahasa inggris (5 slide PPT) terkait topik yang ditentukan oleh PJ Blok (diupload ke MyKlass blok 16)
- **Mahasiswa yang tidak memenuhi 75% kehadiran tidak diijinkan mengikuti SOCA blok 16**

TUGAS PLENARY BAHASA (sebagai nilai tugas mandiri)

PRESENTASI JURNAL EBD TERBAIK DARI KEGIATAN TUTORIAL

- TUTORIAL 1 & 8: SCENARIO PBL 2 (TOOTH EXTRACTION)
- TUTORIAL 2 & 7: SCENARIO CBL 1 (IMPACTION TOOTH)
- TUTORIAL 3 & 6: SCENARIO CBL 2 (ABCESS)
- TUTORIAL 4 & 5: SCENARIO PBL 3 (DENTOALVEOLAR FRACTURE)

- **TIAP KELOMPOK MEMBUAT PPT (5 - 7 slide)** berisi rangkuman singkat isi jurnal yang dianggap merupakan informasi penting yang perlu di share pada kelompok lainnya untuk menjadi pembelajaran bersama

- Waktu presentasi 15 menit /kelompok (2 mhs sebagai presenter per kelompok)

SCENARIO PBL 1 (Anesthesia)

A 45-year old woman visits a dentist to have her lower molar extracted. There is only the root left, but it is not wobbly. From history taking, it is revealed that she has a history of hypertension. On physical examination, her blood pressure is 155/90 mmHg. The dentist chooses anesthesia substance that does not contain vasoconstrictor agent to prevent complication. The dentist also prefers to perform infiltration anesthesia before extracting the patient's tooth.

NOTED : Sekaligus topik Plenary Discussion

SCENARIO PBL 2 (tooth extraction)

A 25-year-old man visits a dentist to have his right upper molar tooth extracted because it is felt painful when it is used for chewing and it has big cavity. However, the clinical examination shows that tooth extraction has to be postponed. Following the dentist's instruction, the patient comes back to the clinic 4 days later. To prevent complication that may occur during tooth extraction, the dentist performs complete examination and extraction preparation.

SCENARIO CBL 1 (Impaction tooth)

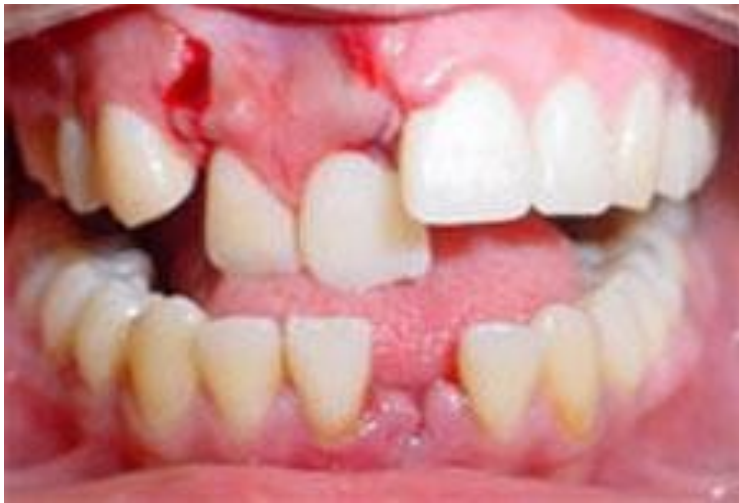A 28-year-old woman came to RSGM with complaints of missing pain arising in the lower left back teeth, more often accompanied by unexplained headaches. The patient also had swollen gums in the area about a week ago. Intra oral examination found 38 teeth did not erupt. Radiological examination showed that tooth 38 was entirely in the mandibular ramus and the position of the crown was below the cervical tooth 37

SCENARIO CBL 2 (Abscess)

A 20-year-old man came to RSGMP with complaints of swelling in the left lower jaw since 5 days ago. The patient said that 1 year ago his left molars had been painful. Currently the swelling is getting bigger, pain and fever patients. Clinical examination results show swelling in the left lower jaw, unclear boundaries, redness, soft consistency, no fluctuations, and tenderness. Intra oral examination revealed 36 dental pulp necrosis, there were elevations of the buccal fold regions 36 and 37, unclear boundaries, redness, soft consistency, fluctuations and tenderness.

SCENARIO PBL 3 (Dentoalveolar Fracture)

A 23-year-old female patient went to the hospital emergency room. There was an opened wound bleeding around upper lip and she couldn't chewing. The intra oral examination showed that 11 and 12 tooth was luxation and traumatic occlusion. The radiographic discription was fractur alveolar 11 and 12. General examination : blood pressure: 110/80mm/Hg and respiration: 20 times/minute.



SCENARIO CBL 3 (Neoplasma)

A 27-year-old man came to RSGM with complaints of growing swelling that has been getting bigger since 6 months ago in the lower right jaw. Extra oral examination found facial asymmetry, solid palpation with firm boundaries. Intra oral examination revealed swelling of the right lower molar region that extended to the lingual, shifting of the teeth around the swelling, dense consistency of elasticity and the same color as the surrounding tissue. Radiological examination showed multilocular radiolucent lesions with soap bubble appearance and root resorption and tooth shifting 48 from their original place.

Referensi

- Arthur, HJ. 2022. *Mosby's Dental Drug Reference*. 13rd ed. Elsevier.
- Block, MS. 2014. *Color Atlas of Dental Implant Surgery, 4th ed*. Saunders, Elsevier.
- Baart, JA., Brand, HS. 2017. *Local Anesthesia in Dentistry*. 2nd ed. Springer.
- Bagheri, SC. 2022. *Clinical Review of Oral and Maxillofacial Surgery, 2nd ed*. Saunders, Elsevier.
- Fonseca, RJ. 2016. *Oral and Maxillofacial Surgery, 3th ed*. Saunders, Elsevier.
- Hupp, J., Tucker, M. and Ellis, E., 2018. *Contemporary Oral and Maxillofacial Surgery, 7th ed*. Mosby, Elsevier.
- Jevon, P. 2014. *Basic Guide to Medical Emergencies in the Dental Practice*. 2nd ed. Wiley, Blackwell.
- Norton, NS. 2017. *Netter's Head and Neck Anatomy for Dentistry*. 3rd ed. Saunders, Elsevier.
- Pedlar, J. 2001. *Oral and Maxillo Surgery. 1st ed*. Churchill Livingstone.
- Kaban, LB., Troulis, MJ., 2004. *Pediatric Oral and Maxillofacial Surgery*. Saunders, Elsevier.
- Miall, L., Rudolf, M., Smith, D. 2012. *Paediatric at a Glance*. 3rd ed. Wiley, Blackwell.
- White, SC and Pharoah, MJ. 2014. *Oral Radiology Principles and Interpretation 7th ed*. Elsevier.